Issue 4, Year 2, Volume 1, No. 02, July-December 2026
E-ISSN: 3122-3591, P-ISSN: 3122-3753
Review International Science Journal

Beyond Estrogen Deficiency: Hormonal Influences, Diagnostic Challenges, and Integrated Management of Vulvar Dermatoses During Menopause

Javier Emanuel Camacho-Patiño.
Independiente
jav.camacho.p@gmail.com
https://orcid.org/0009-0001-6427-3484

Erika Romina Cuenca Riascos
Independiente
romycr_1998@hotmail.com
https://orcid.org/0009-0000-2194-2337

Guillermo Andres Díaz León
Universidad FUCS
guillerdiaz97@outlook.es
https://orcid.org/0009-0001-2023-2306

Mireya Paola Almeida Alvarado
Universidad católica del Ecuador
mireyalmeida94@gmail.com
https://orcid.org/0000-0001-9353-8421

Luis Felipe Espinal Pérez
Independiente
Lufeers@gmail.com
https://orcid.org/0009-0000-6607-2128

Camilo José Izquierdo Flores
Independiente
camiloizquierdoflores@gmail.com
https://orcid.org/0000-0002-8670-5508

Katherine Paola Hidalgo Chuquimarca
Independiente
katheh.2906@gmail.com
https://orcid.org/0009-0008-2026-806X

Javier José Ordoñez Conrado
Universidad Simón Bolivar
javier.ordonez@unisimon.edu.co
https://orcid.org/0009-0000-6989-4370

Received: 25-Oct-2026 | **Accepted: 25-Oct-2026** | **Published: 31-Oct-2026**

*** Corresponding Author:** jav.camacho.p@gmail.com

How to cite this article: Camacho-Patiño, J. E., Díaz León, G. A., Espinal Pérez, L. F., Hidalgo Chuquimarca, K. P., Cuenca Riascos, E. R., Almeida Alvarado, M. P., Izquierdo Flores, C. J., & Ordoñez Conrado, J. J. (2026). Beyond Estrogen Deficiency: Hormonal Influences, Diagnostic Challenges, and Integrated Management of Vulvar Dermatoses During Menopause. México. *International Science Journal* "TheSci". 4 (1) 582-609. Quality Consulting Instituto de Educación Capacitación y Certificación de México. https://ieccmexico.com/thesci

Copyright (c). 2026 Camacho-Patiño, J. E., Díaz León, G. A., Espinal Pérez, L. F., Hidalgo Chuquimarca, K. P., Cuenca Riascos, E. R., Almeida Alvarado, M. P., Izquierdo Flores, C. J., & Ordoñez Conrado, J. J.; This is an open access article distributed under the terms of the Attribution 4.0 International (CC BY-NC-SA 4.0). *International Science Journal* "TheSci". Mexico Review/ Vol. 4, N. 1 / pp. 582-609/ July-December 2026 / e-ISSN: 3122-3591 / p-ISSN: 3122-3753. Research Article

ABSTRACT

The menopausal transition is associated with significant endocrine, epithelial, and immunological changes that influence vulvar health and may complicate the recognition of inflammatory and autoimmune dermatological disorders. This narrative review aimed to analyze the relationship between menopausal hormonal alterations and vulvar dermatoses, emphasizing pathophysiological mechanisms, clinical manifestations, differential diagnosis, and evidence-based therapeutic strategies. A qualitative synthesis of 20 scientific publications was conducted, incorporating international clinical research, epidemiological investigations, reviews, and professional guidelines, including evidence from Latin America. The findings identified estrogen deficiency as an important contributor to epithelial fragility, reduced lubrication, altered vaginal microbiota, and genitourinary syndrome of menopause. However, these alterations frequently

Issue 4, Year 2, Volume 1, No. 02, July-December 2026
E-ISSN: 3122-3591, P-ISSN: 3122-3753
Review International Science Journal

coexist with independent conditions, including lichen sclerosus, erosive lichen planus, contact dermatitis, lichen simplex chronicus, and genital psoriasis. Considerable overlap was observed in symptoms such as pruritus, burning, dryness, and dyspareunia, whereas characteristic morphological findings provided greater diagnostic differentiation. Epidemiological evidence demonstrated substantial variability in the reported prevalence of menopausal genitourinary symptoms, with relevant findings from a Brazilian population-based study. Therapeutic approaches differed according to the underlying condition, with local hormonal treatments and nonhormonal interventions primarily indicated for genitourinary syndrome of menopause, while topical anti-inflammatory agents remained central to the management of inflammatory dermatoses. The available evidence also highlighted uncertainties surrounding emerging therapeutic technologies and the limited representation of Latin American populations. In conclusion, vulvar disorders during the menopausal transition require comprehensive evaluation that distinguishes hormonal tissue changes from independent inflammatory diseases. An integrated dermatological, gynecological, and endocrinological approach is essential for accurate diagnosis, individualized treatment, and appropriate long-term clinical surveillance.

KEYWORDS

vulvar dermatoses, menopause, perimenopause, estrogen deficiency, genitourinary syndrome of menopause, vulvar lichen sclerosus, lichen planus, vulvar dermatitis, differential diagnosis, hormonal changes, vulvar health, therapeutic management

INTRODUCTION

The menopausal transition is characterized by progressive changes in ovarian function, hormonal fluctuations, and declining estrogen concentrations that influence the structural and functional integrity of vulvovaginal tissues. These modifications may contribute to epithelial thinning, reduced lubrication, altered local immune responses, and increased susceptibility to irritation and inflammation. However, vulvar symptoms during this period cannot be attributed exclusively to hormonal deficiency, as several inflammatory, autoimmune, and infectious dermatological conditions may coexist with menopausal changes. This clinical overlap represents a significant challenge for gynecologists, dermatologists, and endocrinologists, particularly when persistent symptoms are initially interpreted as physiological consequences of aging [1], [4], [7].

Genitourinary syndrome of menopause (GSM) is among the most frequently recognized conditions affecting genital health in midlife and postmenopausal women. Its manifestations include vulvovaginal dryness, burning, pruritus, dyspareunia, and urinary discomfort, with considerable variation in symptom severity and clinical presentation. Epidemiological investigations have demonstrated its substantial prevalence across different populations, including Latin American women. A population-based study conducted in Brazil highlighted the relevance of GSM as a public health concern, while international systematic reviews have emphasized persistent challenges regarding recognition, assessment, and adequate treatment [3], [9], [11]. Nevertheless, the coexistence of hormonal alterations and vulvar dermatoses complicates the interpretation of genital symptoms and may contribute to delayed diagnosis.

Among the principal dermatological conditions affecting this anatomical region, lichen sclerosus, erosive lichen planus, contact dermatitis, lichen simplex chronicus, and genital psoriasis deserve particular attention. These disorders may share manifestations such as itching, erythema, burning, and pain, although their underlying mechanisms, morphological characteristics, and therapeutic requirements differ considerably. Lichen sclerosus is particularly relevant because of its chronic inflammatory nature, potential for progressive anatomical changes, and association with vulvar squamous cell carcinoma. Similarly, erosive lichen planus may produce persistent inflammation, mucosal erosions, and scarring. Accurate differentiation between these conditions and estrogen-deficiency-related changes is therefore essential to prevent diagnostic delays and avoid inappropriate treatment [5], [12]–[15], [19].

Hormonal influences on vulvar health also involve interactions between epithelial physiology, vaginal microbiota, inflammatory pathways, and tissue repair mechanisms. Estrogen depletion contributes to changes in epithelial maturation and the local microbial environment, potentially modifying tissue vulnerability and symptom expression. Nevertheless, the relationship between endocrine changes and inflammatory vulvar disease remains insufficiently

Issue 4, Year 2, Volume 1, No. 02, July-December 2026
E-ISSN: 3122-3591, P-ISSN: 3122-3753
Review International Science Journal

understood, particularly regarding whether menopausal alterations contribute to disease onset, aggravate preexisting dermatoses, or primarily modify their clinical presentation [4], [10], [17], [20].

From a therapeutic perspective, optimal management requires an individualized approach that integrates hormonal evaluation, detailed vulvar examination, identification of associated dermatological conditions, and appropriate selection of pharmacological and supportive interventions. While local hormonal therapies may relieve symptoms associated with GSM, inflammatory dermatoses frequently require targeted treatments, including topical corticosteroids and long-term clinical surveillance. Emerging therapeutic approaches have also generated interest; however, their efficacy and long-term safety require careful evaluation before widespread clinical implementation [1], [8], [11], [13].

Accordingly, this narrative review aims to examine the relationship between menopausal hormonal changes and vulvar dermatoses, emphasizing their pathophysiological mechanisms, clinical manifestations, differential diagnosis, and evidence-based management. Drawing on international clinical studies, systematic reviews, and practice guidelines, including evidence from Latin America, the analysis addresses three central questions: how menopausal endocrine changes influence vulvar tissue susceptibility, which clinical findings facilitate differentiation between GSM and inflammatory dermatoses, and which therapeutic strategies provide the most appropriate individualized care. By integrating dermatological, gynecological, and endocrinological perspectives, this review seeks to contribute to a more comprehensive understanding of vulvar disorders during the menopausal transition.

DEVELOPMENT

Hormonal Changes During the Menopausal Transition and Their Influence on Vulvar Health

The menopausal transition involves a progressive decline in ovarian follicular activity, accompanied by fluctuations in estradiol, progesterone, and gonadotropin concentrations. These endocrine changes influence the physiological characteristics of estrogen-responsive tissues, particularly the vaginal epithelium, vestibule, and surrounding vulvar structures. Estrogen contributes to epithelial maturation, tissue hydration, vascularization, and the maintenance of the local microenvironment. As ovarian estrogen production decreases, genital tissues may develop greater fragility, reduced elasticity, impaired lubrication, and increased sensitivity to mechanical or chemical irritation [4], [7], [17].

Nevertheless, hormonal changes do not affect all vulvar structures uniformly. The vulva contains both keratinized and nonkeratinized epithelial surfaces, each with distinct anatomical properties and hormonal responsiveness. Consequently, menopausal tissue changes may coexist with inflammatory conditions without necessarily representing their primary cause. This distinction is clinically relevant because symptoms such as pruritus, burning, and discomfort frequently overlap across endocrine and dermatological disorders. The presence of persistent vulvar complaints therefore requires an evaluation that extends beyond the identification of estrogen deficiency [1], [18], [19].

Changes in the vaginal microbial environment represent another important component of menopausal physiology. Declining estrogen concentrations reduce epithelial glycogen availability and may contribute to a lower relative abundance of *Lactobacillus* species, increased vaginal pH, and alterations in microbial community composition. Brotman et al. demonstrated an association between menopausal status, vaginal microbiota composition, and signs of vulvovaginal atrophy, supporting the interaction between endocrine physiology and the local microbial environment. However, these associations should not be interpreted as evidence that microbiota alterations independently cause specific inflammatory vulvar dermatoses [20].

Genitourinary Syndrome of Menopause and Its Clinical Relevance

Genitourinary syndrome of menopause encompasses genital, sexual, and urinary manifestations associated with menopause-related changes in sex steroid concentrations. Unlike isolated vulvovaginal dryness, GSM includes a broader spectrum of symptoms involving multiple anatomical structures. Common manifestations include dryness, burning, irritation, reduced lubrication, dyspareunia, dysuria, and urinary urgency. These symptoms may persist or progress without appropriate management, adversely affecting sexual function, personal comfort, and quality of life [9], [11].

Issue 4, Year 2, Volume 1, No. 02, July-December 2026
E-ISSN: 3122-3591, P-ISSN: 3122-3753
Review International Science Journal

Epidemiological studies have demonstrated considerable variability in GSM prevalence, reflecting differences in diagnostic definitions, population characteristics, and symptom-reporting methods. The systematic review conducted by Mili et al. identified substantial heterogeneity across studies, while population-based research involving Brazilian women provided relevant regional evidence of the syndrome's clinical burden. These findings support the importance of considering sociocultural factors, healthcare accessibility, and patterns of symptom disclosure when evaluating menopausal genital health across international populations [3], [9], [11].

Despite its prevalence, GSM remains an important source of diagnostic uncertainty. Erythema, irritation, pruritus, and dyspareunia may also occur in inflammatory vulvar dermatoses, making symptom-based diagnosis insufficient. Furthermore, estrogen deficiency may coexist with lichen sclerosus, contact dermatitis, or other cutaneous conditions, producing mixed clinical presentations. A comprehensive examination is therefore necessary to determine whether symptoms originate predominantly from hormonal tissue changes, an independent dermatological disorder, or a combination of both [1], [6], [18].

Inflammatory and Autoimmune Vulvar Dermatoses

Lichen sclerosus is a chronic inflammatory disease that predominantly affects the anogenital region and is particularly relevant among peri- and postmenopausal women. Its characteristic manifestations include porcelain-white plaques, epidermal atrophy, fissures, ecchymoses, and progressive changes in vulvar architecture. Advanced disease may lead to labial fusion, clitoral hood scarring, and introital narrowing. Although its etiology is multifactorial and involves immune-mediated mechanisms, genetic susceptibility, and other biological factors, menopause should not be considered its direct cause [5], [13], [15].

The clinical significance of lichen sclerosus extends beyond symptomatic discomfort. Persistent inflammation and inadequate disease control may contribute to irreversible anatomical changes and are associated with an increased risk of vulvar squamous cell carcinoma. Accordingly, early recognition, appropriate anti-inflammatory treatment, and long-term surveillance are essential components of clinical management. Ultrahigh-potency topical corticosteroids, particularly clobetasol propionate 0.05%, constitute the principal first-line therapeutic option, with treatment subsequently adjusted according to clinical response and disease activity [5], [12], [13].

Vulvar lichen planus represents another important immune-mediated disorder, particularly when erosive lesions affect mucosal surfaces. Patients may experience intense burning, pain, dyspareunia, and persistent erythematous or erosive lesions. In severe cases, chronic inflammation may produce adhesions, scarring, and anatomical distortion. Unlike isolated GSM, erosive lichen planus often presents with inflammatory mucosal abnormalities that require targeted dermatological assessment. Management generally involves potent topical anti-inflammatory therapies, while refractory cases may require specialist-directed systemic treatment [14], [19].

Contact dermatitis, lichen simplex chronicus, and genital psoriasis further expand the differential diagnosis. Contact dermatitis may result from irritant exposure or delayed hypersensitivity reactions involving hygiene products, fragrances, topical medications, sanitary materials, or other substances. Lichen simplex chronicus is frequently associated with repetitive scratching and chronic disruption of the itch–scratch cycle. Genital psoriasis may present as sharply demarcated erythematous plaques with minimal scaling because of the local moisture and friction characteristic of intertriginous surfaces. These distinctions are essential because each condition requires identification of specific triggers and individualized anti-inflammatory or barrier-protective interventions [2], [10], [19].

Differential Diagnosis and Clinical Assessment

The differential diagnosis of vulvar dermatoses during the menopausal transition requires careful integration of symptom history, lesion morphology, anatomical distribution, and associated systemic findings. Although hormonal atrophy commonly produces diffuse dryness, pallor, and epithelial fragility, inflammatory disorders may demonstrate more distinctive characteristics, including well-demarcated plaques, hyperkeratosis, erosions, fissures, or progressive architectural distortion. Persistent focal abnormalities should therefore not be attributed to menopausal atrophy without further evaluation [6], [12], [16].

Issue 4, Year 2, Volume 1, No. 02, July-December 2026
E-ISSN: 3122-3591, P-ISSN: 3122-3753
Review International Science Journal

A comprehensive clinical assessment should include the duration and progression of symptoms, exposure to potential irritants, previous therapeutic responses, sexual discomfort, and relevant medical history. Direct examination remains central to diagnosis, while additional investigations should be selected according to the suspected condition. Microbiological testing may be appropriate when infection is suspected, and patch testing may help identify allergic contact dermatitis. Vulvar biopsy is indicated when the diagnosis remains uncertain, lesions are treatment-resistant, or findings raise concern for vulvar intraepithelial neoplasia or invasive malignancy. Particular attention should be given to persistent ulceration, unexplained pigmentation, focal thickening, and lesions that fail to respond to appropriate therapy [2], [5], [12].

The diagnostic process is particularly challenging when more than one condition is present. For example, an individual with GSM may simultaneously develop lichen sclerosus or irritant contact dermatitis, resulting in overlapping symptoms that persist despite estrogen-based treatment. Recognizing these combined presentations allows clinicians to avoid therapeutic oversimplification and supports an individualized approach based on the identification of all clinically relevant contributing factors [1], [6], [18].

Integrated Therapeutic Management

The management of vulvar dermatoses during the menopausal transition should be guided by the underlying diagnosis, severity of symptoms, extent of tissue involvement, and individual treatment preferences. General vulvar care measures, including avoidance of irritants, gentle cleansing, reduction of excessive friction, and appropriate use of emollients, represent useful supportive interventions across several conditions. Nevertheless, these strategies should complement rather than replace disease-specific treatment [1], [2], [10].

For GSM, vaginal moisturizers and lubricants may provide symptomatic relief in mild cases, while low-dose vaginal estrogen preparations are established therapeutic options for persistent moderate-to-severe symptoms. Other treatments, including vaginal dehydroepiandrosterone and ospemifene, may be considered according to clinical indications, contraindications, availability, and patient preferences. In contrast, inflammatory dermatoses generally require targeted anti-inflammatory therapy. Lichen sclerosus is primarily treated with potent or ultrapotent topical corticosteroids, whereas erosive lichen planus and other refractory inflammatory disorders may require additional specialist-directed interventions [11], [13], [14].

Energy-based treatments, including vaginal laser procedures, have attracted interest as potential alternatives for menopausal genital symptoms. However, available evidence has not consistently established their long-term effectiveness and safety, particularly when compared with established treatments. Consequently, such interventions should not routinely replace evidence-based hormonal or dermatological therapies [8], [11].

Finally, long-term follow-up is particularly important for chronic inflammatory vulvar conditions. Treatment effectiveness should be assessed through symptom improvement, resolution of inflammatory findings, preservation of anatomical structures, and detection of potentially suspicious lesions. Multidisciplinary collaboration between dermatology, gynecology, and endocrinology may facilitate comprehensive management, particularly in complex cases involving overlapping hormonal and inflammatory mechanisms [1], [5], [12].

GENERAL OBJECTIVE AND SPECIFIC OBJECTIVES

To critically analyze the relationship between hormonal changes during the menopausal transition and the development, clinical presentation, differential diagnosis, and therapeutic management of vulvar dermatoses through an integrative review of international scientific literature, emphasizing endocrine mechanisms, inflammatory processes, and evidence-based clinical strategies to strengthen multidisciplinary understanding and promote comprehensive care for peri- and postmenopausal women.

Specific Objectives

Cognitive Domain

Issue 4, Year 2, Volume 1, No. 02, July-December 2026
E-ISSN: 3122-3591, P-ISSN: 3122-3753
Review International Science Journal

Identify: To recognize the principal hormonal, epithelial, immunological, and microbiological changes occurring during the menopausal transition and describe their potential influence on vulvar health and susceptibility to inflammatory disorders [4], [7], [20].

Understand: To explain the pathophysiological mechanisms and clinical characteristics of genitourinary syndrome of menopause, lichen sclerosus, lichen planus, contact dermatitis, and other relevant vulvar dermatoses [5], [9], [13], [19].

Analyze: To differentiate estrogen-deficiency-related manifestations from inflammatory, autoimmune, infectious, and potentially neoplastic vulvar conditions through the comparative examination of clinical findings and diagnostic criteria [6], [12], [18].

Evaluate: To critically assess the effectiveness, limitations, and safety of available hormonal, pharmacological, and supportive therapeutic interventions based on published scientific evidence [8], [11], [14].

Psychomotor Domain

Apply: To organize evidence-based clinical assessment procedures into a structured diagnostic framework incorporating symptom characterization, anatomical examination, lesion morphology, and appropriate indications for complementary investigations [1], [6], [12].

Demonstrate: To develop a practical differential diagnostic pathway illustrating the sequential evaluation of vulvar symptoms and supporting the distinction between hormonal atrophy and inflammatory dermatoses [2], [5], [18].

Integrate: To construct an evidence-informed clinical management framework combining dermatological and gynecological assessment, therapeutic selection, and follow-up considerations for patients presenting with overlapping hormonal and inflammatory manifestations [11], [13], [19].

These objectives address procedural and clinical skills through the development of assessment frameworks rather than through direct examination of patients or measurement of practical competencies.

Affective Domain

Recognize: To acknowledge the influence of vulvar symptoms on sexual well-being, daily functioning, emotional health, and quality of life during the menopausal transition [3], [9], [16].

Value: To emphasize the importance of respectful communication, confidentiality, shared decision-making, and sensitivity toward cultural differences in the assessment of intimate health concerns.

Promote: To encourage multidisciplinary collaboration, patient-centered care, and equitable access to diagnostic and therapeutic resources, particularly in healthcare settings where specialized vulvar services may be limited [1], [12].

Prioritize: To reinforce the importance of early recognition, appropriate referral, and longitudinal surveillance of chronic vulvar dermatoses to reduce preventable complications and diagnostic delays [5], [13], [15].

OBJECT OF STUDY

The object of study of this research is the relationship between hormonal changes occurring during the menopausal transition and the clinical development, manifestation, diagnosis, and management of vulvar dermatoses in peri- and postmenopausal women. Particular attention is given to the influence of estrogen deficiency on vulvar epithelial integrity, tissue hydration, local inflammatory responses, and microbial homeostasis, as well as the potential coexistence of these physiological changes with independent inflammatory and autoimmune dermatological disorders [4], [7], [17], [20].

The study focuses on genitourinary syndrome of menopause and its differentiation from relevant vulvar conditions, including lichen sclerosus, erosive lichen planus, contact dermatitis, lichen simplex chronicus, and genital psoriasis. These disorders are examined according to their pathophysiological characteristics, clinical manifestations, morphological findings, diagnostic criteria, and therapeutic approaches. Special consideration is given to overlapping

Issue 4, Year 2, Volume 1, No. 02, July-December 2026
E-ISSN: 3122-3591, P-ISSN: 3122-3753
Review International Science Journal

symptoms, such as pruritus, burning, dryness, dyspareunia, and persistent vulvar irritation, which may complicate diagnostic accuracy and delay appropriate treatment [1], [5], [6], [10], [19].

The population of interest comprises women undergoing the menopausal transition and those in postmenopause, particularly individuals experiencing vulvar symptoms associated with hormonal, inflammatory, or combined pathological mechanisms. Rather than examining patients directly, the research analyzes previously published scientific evidence, including clinical investigations, epidemiological studies, narrative and systematic reviews, and professional recommendations. International findings are considered alongside available Latin American evidence to identify common clinical patterns, differences in epidemiological characterization, and potential limitations in the regional applicability of existing knowledge [3], [9], [11].

The analytical scope encompasses three interconnected dimensions: the biological mechanisms through which menopausal hormonal changes influence vulvar tissues; the clinical and diagnostic characteristics that distinguish estrogen-deficiency-related manifestations from independent dermatological diseases; and the effectiveness, indications, and limitations of available therapeutic interventions. These dimensions are integrated to support a comprehensive understanding of vulvar health during reproductive aging and to identify opportunities for improving diagnostic reasoning, individualized treatment, and multidisciplinary clinical management [8], [12], [13], [14].

Accordingly, the object of study is not limited to the description of individual vulvar diseases but extends to the interaction between endocrine physiology, dermatological pathology, and clinical decision-making during the menopausal transition. This approach provides the conceptual foundation for evaluating existing scientific evidence, recognizing areas of diagnostic uncertainty, and identifying research gaps relevant to the comprehensive care of peri- and postmenopausal women.

METHODOLOGY

Research Design and Approach

This study was developed as a narrative literature review with a descriptive, analytical, and interpretative approach, aimed at examining the relationship between hormonal changes during the menopausal transition and the clinical characteristics, differential diagnosis, and therapeutic management of vulvar dermatoses. The methodological framework was based on the scientific method, integrating the identification of a clinical problem, formulation of research questions, examination of published evidence, comparative analysis of findings, and development of evidence-informed conclusions.

A qualitative approach was selected because the objective was to synthesize existing scientific knowledge rather than measure clinical outcomes in a primary patient population. The review incorporated epidemiological, pathophysiological, diagnostic, and therapeutic perspectives to provide a comprehensive interpretation of vulvar disorders affecting peri- and postmenopausal women [1], [4], [7], [11].

Research Problem and Guiding Questions

The research problem was defined by the diagnostic complexity associated with vulvar symptoms during the menopausal transition. Although estrogen deficiency contributes to epithelial fragility, dryness, and genitourinary discomfort, similar manifestations may arise from inflammatory, autoimmune, infectious, or other dermatological conditions. This overlap can complicate clinical recognition and contribute to inappropriate therapeutic selection [6], [10], [18].

The review was guided by three principal research questions:

1. How do hormonal and epithelial changes during the menopausal transition influence vulvar health and the clinical expression of dermatological disorders?
2. Which clinical and morphological characteristics are most relevant for differentiating genitourinary syndrome of menopause from inflammatory and autoimmune vulvar dermatoses?

Issue 4, Year 2, Volume 1, No. 02, July-December 2026
E-ISSN: 3122-3591, P-ISSN: 3122-3753
Review International Science Journal

3. What therapeutic strategies are supported by the available scientific evidence for the comprehensive management of vulvar disorders in peri- and postmenopausal women?

These questions established the conceptual framework for organizing the literature and interpreting the findings.

Sources of Information and Literature Identification

The documentary analysis was based on a defined corpus of 20 scientific publications dated between 2014 and 2026. The references included clinical investigations, population-based studies, systematic and narrative reviews, and professional recommendations addressing menopausal hormonal changes, genitourinary syndrome of menopause, inflammatory vulvar dermatoses, and therapeutic management.

PubMed/MEDLINE and Scopus were identified as principal bibliographic resources relevant to the subject. The literature-identification framework incorporated combinations of controlled vocabulary and free-text terms related to the menopausal transition and vulvar dermatological disorders.

The principal search concepts included *menopause*, *perimenopause*, *postmenopause*, *vulvar dermatoses*, *genitourinary syndrome of menopause*, *estrogen deficiency*, *vulvar lichen sclerosus*, *lichen planus*, *contact dermatitis*, *vulvar pruritus*, *differential diagnosis*, and *therapeutic management*.

Boolean operators were considered to structure combinations of these concepts and distinguish publications addressing hormonal mechanisms, clinical manifestations, and treatment strategies.

The review was not designed as an exhaustive systematic search. Consequently, no comprehensive screening totals, formal study-selection flow, or quantitative synthesis were established.

Eligibility and Selection Criteria

Publications were considered relevant when they addressed at least one of the following dimensions: menopausal endocrine changes affecting vulvovaginal tissues; epidemiology and clinical characteristics of genitourinary syndrome of menopause; pathophysiology and diagnosis of inflammatory vulvar dermatoses; differential diagnosis of persistent vulvar symptoms; or evidence-based therapeutic interventions.

Priority was given to peer-reviewed publications with clear clinical relevance, recognized professional recommendations, and studies providing information applicable to the diagnostic or therapeutic challenges identified in the research questions.

Studies focusing exclusively on unrelated dermatological conditions, publications without a meaningful connection to vulvar health, and sources lacking sufficient clinical or scientific relevance were considered outside the scope of the review.

Evidence from Latin America was incorporated when available to support a broader geographical perspective and identify limitations in the regional representation of menopausal vulvar health research [3].

Organization and Extraction of Information

The selected literature was organized into thematic categories corresponding to the principal objectives of the review. These categories included hormonal and epithelial changes, alterations in the vaginal microbial environment, genitourinary syndrome of menopause, inflammatory and autoimmune vulvar dermatoses, diagnostic differentiation, and therapeutic management.

Information was extracted at a conceptual level, emphasizing study objectives, principal findings, clinical implications, and methodological limitations. Particular attention was given to distinguishing observations supported by clinical investigations from interpretations proposed in narrative reviews and professional recommendations.

Epidemiological findings were examined according to their populations, diagnostic definitions, and reported outcomes. This approach was necessary because the prevalence of menopausal genitourinary symptoms varies considerably across studies and cannot be interpreted independently of methodological differences [3], [9], [11].

Issue 4, Year 2, Volume 1, No. 02, July-December 2026
E-ISSN: 3122-3591, P-ISSN: 3122-3753
Review International Science Journal

Critical Analysis and Evidence Synthesis

The analytical process involved comparing findings across the selected publications to identify areas of agreement, uncertainty, and potential contradiction.

Evidence concerning hormonal physiology was examined alongside research addressing vulvar inflammation and epithelial alterations. Similarly, diagnostic recommendations were compared to determine which clinical characteristics were most useful for distinguishing estrogen-deficiency-related manifestations from independent inflammatory disorders [4], [5], [12], [20].

Therapeutic evidence was analyzed according to the underlying disease mechanism, reported clinical indications, and limitations of available interventions. Established approaches, including local hormonal therapy for genitourinary syndrome of menopause and topical corticosteroids for lichen sclerosus, were differentiated from emerging interventions for which long-term effectiveness and safety remain uncertain [8], [11], [13].

The synthesis was qualitative and interpretative. No meta-analysis, pooled prevalence estimate, comparative effect-size calculation, or formal statistical hypothesis testing was performed.

Development of Figures and Analytical Frameworks

Five figures were developed to organize and communicate the principal findings of the literature review.

The first figure summarized the expected relationships between menopausal endocrine changes and vulvovaginal epithelial characteristics. The second presented selected epidemiological estimates related to genitourinary syndrome of menopause. The third compared characteristic clinical manifestations of major vulvar dermatoses. The fourth organized an evidence-informed diagnostic pathway, while the fifth summarized therapeutic approaches according to the underlying condition.

These figures served as visual instruments for conceptual synthesis and comparative interpretation. They did not represent original patient measurements, prospectively validated clinical algorithms, or pooled statistical analyses. Their purpose was to facilitate the interpretation of the reviewed evidence and highlight clinically relevant distinctions.

Ethical Considerations

The study was based exclusively on previously published scientific literature and did not involve direct patient participation, collection of identifiable personal information, experimental procedures, or interventions involving human subjects.

Accordingly, no individual informed consent process was required for the development of this narrative review. The analysis was conducted with attention to accurate scientific interpretation, appropriate attribution of published findings, and avoidance of unsupported causal conclusions.

Methodological Limitations

The principal methodological limitation was the narrative design, which does not provide the same degree of reproducibility or control of selection bias as a systematic review.

The relatively limited corpus of publications and the heterogeneity of study populations, diagnostic definitions, and therapeutic outcomes restricted direct comparisons across sources. Furthermore, evidence specifically examining the coexistence of genitourinary syndrome of menopause and inflammatory vulvar dermatoses remains less developed than research addressing these conditions independently.

The limited representation of Latin American populations also restricted the ability to generalize international findings to different regional healthcare environments.

Despite these limitations, the methodological approach permitted an integrated examination of endocrine, dermatological, and gynecological evidence, providing a clinically oriented synthesis of the principal diagnostic and therapeutic considerations associated with vulvar dermatoses during the menopausal transition.

Issue 4, Year 2, Volume 1, No. 02, July-December 2026
E-ISSN: 3122-3591, P-ISSN: 3122-3753
Review International Science Journal

PHASES OF DEVELOPMENT

Phase 1. Identification and Delimitation of the Research Problem

The initial phase focused on identifying the clinical challenges associated with vulvar disorders during the menopausal transition, particularly the difficulty of distinguishing estrogen-deficiency-related manifestations from inflammatory and autoimmune dermatological conditions.

The research problem was established through the recognition that symptoms such as pruritus, burning, dryness, irritation, and dyspareunia may occur in genitourinary syndrome of menopause and in several independent vulvar dermatoses. This symptomatic overlap can complicate diagnostic accuracy and contribute to delayed recognition of conditions requiring specific treatment [1], [6], [18].

The scope of the investigation was subsequently delimited to the relationship between menopausal hormonal changes, vulvar epithelial alterations, inflammatory dermatoses, differential diagnosis, and therapeutic management.

Phase 2. Formulation of Research Questions and Objectives

The second phase involved defining the general and specific objectives and establishing the principal questions guiding the review.

The research questions addressed the influence of hormonal changes on vulvar health, the clinical characteristics distinguishing major vulvar disorders, and the therapeutic interventions supported by available scientific evidence.

The objectives were structured according to cognitive, psychomotor, and affective domains, incorporating the identification of biological mechanisms, comparative analysis of clinical manifestations, development of diagnostic frameworks, and recognition of patient-centered considerations.

The guiding premise was that estrogen deficiency contributes to vulvar tissue changes but does not independently explain all inflammatory and autoimmune disorders occurring during the menopausal transition [4], [5], [17].

Phase 3. Identification and Organization of Scientific Evidence

The third phase consisted of organizing a documentary corpus of 20 scientific publications dated between 2014 and 2026.

The literature included clinical investigations, epidemiological studies, scientific reviews, and professional recommendations addressing menopausal endocrine physiology, genitourinary syndrome of menopause, inflammatory vulvar dermatoses, diagnostic assessment, and therapeutic management.

PubMed/MEDLINE and Scopus were considered principal bibliographic resources for the literature-identification framework. Relevant concepts included menopause, perimenopause, vulvar dermatoses, estrogen deficiency, lichen sclerosus, lichen planus, vulvar dermatitis, and differential diagnosis.

The publications were organized according to their contribution to the research questions. Particular attention was given to international evidence and available Latin American investigations to support a geographically inclusive interpretation of the subject [3], [9], [11].

Phase 4. Classification and Thematic Analysis of Information

During the fourth phase, the scientific evidence was classified into thematic categories to facilitate comparison and interpretation.

The first category addressed endocrine and epithelial changes associated with reproductive aging, including alterations in estrogen concentrations, tissue hydration, epithelial maturation, and microbial composition [4], [17], [20].

The second category examined genitourinary syndrome of menopause, emphasizing its epidemiological characteristics, clinical manifestations, and relationship with estrogen deficiency [3], [9], [11].

Issue 4, Year 2, Volume 1, No. 02, July-December 2026
E-ISSN: 3122-3591, P-ISSN: 3122-3753
Review International Science Journal

The third category focused on inflammatory and autoimmune vulvar dermatoses, particularly lichen sclerosus, erosive lichen planus, contact dermatitis, lichen simplex chronicus, and genital psoriasis [2], [5], [13], [14], [19].

The remaining categories addressed differential diagnosis, clinical evaluation, therapeutic interventions, and long-term follow-up.

This classification enabled the identification of shared clinical characteristics and disease-specific findings without assuming that all vulvar manifestations during menopause arise from the same pathological mechanism.

Phase 5. Comparative Evaluation and Critical Interpretation

The fifth phase involved comparing the selected publications to identify consistent findings, differences in clinical recommendations, and limitations in the available evidence.

The analysis examined the relationship between hormonal alterations and vulvar tissue changes, distinguishing established physiological associations from proposed mechanisms that remain incompletely understood.

Particular attention was given to the diagnostic overlap between genitourinary syndrome of menopause and inflammatory vulvar disorders. Clinical features such as white sclerotic plaques, persistent erosions, lichenification, and anatomical distortion were evaluated as potential distinguishing characteristics [5], [10], [12], [18].

Therapeutic evidence was also compared to differentiate established interventions from approaches supported by more limited or heterogeneous findings. This included examining local hormonal treatments, topical corticosteroids, supportive vulvar care, and emerging energy-based procedures [8], [11], [13], [14].

The interpretation remained qualitative, without calculating pooled estimates or introducing statistical outcomes not reported in the selected literature.

Phase 6. Integration of Findings and Development of Analytical Figures

The sixth phase focused on integrating the findings into a coherent clinical and scientific framework.

Five figures were developed to summarize the principal dimensions of the review.

Figure 1 illustrated the conceptual relationship between menopausal hormonal changes and vulvovaginal epithelial characteristics.

Figure 2 summarized selected epidemiological estimates concerning genitourinary syndrome of menopause, highlighting variability across international studies and the contribution of Latin American evidence.

Figure 3 compared the characteristic clinical manifestations of major vulvar dermatoses.

Figure 4 organized an evidence-informed diagnostic pathway for evaluating vulvar symptoms during the menopausal transition.

Figure 5 presented a comparative framework of therapeutic approaches according to the underlying dermatological or hormonal condition.

These figures were designed as instruments for organizing and interpreting the literature rather than as representations of original clinical data or prospectively validated diagnostic models.

Phase 7. Scientific Synthesis, Discussion, and Conclusions

The final phase consisted of integrating the analyzed evidence into a comprehensive discussion and developing conclusions aligned with the research objectives.

The discussion examined the clinical significance of hormonal and inflammatory interactions, the limitations of symptom-based diagnosis, and the importance of recognizing coexisting vulvar conditions.

Issue 4, Year 2, Volume 1, No. 02, July-December 2026
E-ISSN: 3122-3591, P-ISSN: 3122-3753
Review International Science Journal

The therapeutic implications were evaluated according to the need for individualized treatment, appropriate specialist referral, and long-term surveillance of chronic inflammatory diseases.

Methodological limitations were also considered, including the narrative design, heterogeneity of the selected publications, and limited availability of region-specific evidence.

Finally, the conclusions emphasized the importance of distinguishing physiological menopausal changes from independent vulvar dermatoses and integrating dermatological, gynecological, and endocrinological perspectives to improve diagnostic reasoning and therapeutic decision-making [1], [5], [11], [12].

The completion of these phases provided a structured foundation for synthesizing the available scientific literature and identifying opportunities for future research into vulvar health during the menopausal transition.

RESULTS AND DISCUSSION

Figure 1.
Hormonal and Epithelial Alterations Associated With the Menopausal Transition

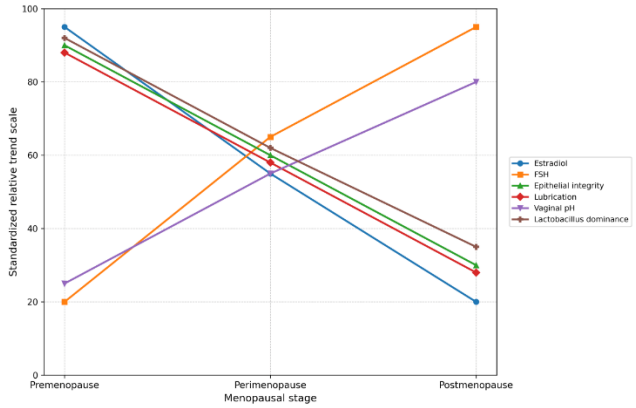

Figure 1 illustrates the progressive hormonal and epithelial modifications associated with the transition from reproductive age to postmenopause, emphasizing the relationship between declining estrogen concentrations, compensatory changes in follicle-stimulating hormone (FSH), and alterations in vulvovaginal tissue characteristics. The graphical representation integrates several physiological variables, including estradiol levels, epithelial integrity, lubrication, vaginal pH, and the relative predominance of *Lactobacillus* species. These variables are presented as conceptual trends rather than measurements obtained from a specific clinical population, allowing the visualization of biological relationships described in the scientific literature [4], [7], [17].

During the premenopausal stage, ovarian estrogen production contributes to the maintenance of epithelial maturation, adequate tissue hydration, vascularization, and genital elasticity. Estradiol supports the proliferation and differentiation of estrogen-responsive epithelial cells, promoting the structural and functional characteristics necessary for vulvovaginal homeostasis. Under these conditions, the vaginal epithelium generally maintains greater thickness and glycogen availability, supporting a microbial environment frequently dominated by *Lactobacillus* species. These microorganisms contribute to the production of lactic acid and the maintenance of an acidic vaginal environment, although microbial composition varies among individuals [17], [20].

As women enter perimenopause, fluctuations in ovarian function produce increasing variability in circulating estradiol concentrations. These endocrine changes are accompanied by alterations in hypothalamic-pituitary-ovarian feedback mechanisms, resulting in a general tendency toward elevated FSH concentrations, although individual hormone measurements may fluctuate considerably throughout this stage. The figure represents these changes through opposing conceptual trajectories, with estradiol progressively decreasing and FSH increasing as reproductive aging advances. This relationship reflects the physiological transition toward ovarian follicular depletion rather than a uniform or strictly linear hormonal process [4], [7].

The reduction in estrogenic stimulation contributes to progressive changes in vulvovaginal epithelial structure and function. Decreased epithelial maturation, reduced tissue hydration, and diminished elasticity may increase susceptibility to friction-related discomfort and mechanical irritation. Simultaneously, alterations in local secretory activity and epithelial characteristics can contribute to reduced lubrication and the development of symptoms such as dryness, burning, and dyspareunia. These manifestations constitute important components of genitourinary syndrome

Issue 4, Year 2, Volume 1, No. 02, July-December 2026
E-ISSN: 3122-3591, P-ISSN: 3122-3753
Review International Science Journal

of menopause, although their intensity and clinical presentation vary considerably among affected women [9], [11], [16].

Another relevant relationship illustrated in Figure 1 concerns the interaction between hormonal status, epithelial glycogen availability, and vaginal microbial composition. Estrogen deficiency may reduce the availability of glycogen-associated substrates within the vaginal environment, contributing to changes in the relative abundance of *Lactobacillus* species and an increase in vaginal pH. Brotman et al. identified associations between menopausal status, microbial community composition, and signs of vulvovaginal atrophy, supporting the biological relationship between reproductive aging and vaginal microbial ecology. Nevertheless, these findings do not establish that changes in the microbiota directly cause inflammatory or autoimmune vulvar diseases [20].

During postmenopause, sustained reductions in ovarian estrogen production are associated with a greater likelihood of persistent epithelial and functional alterations. The figure depicts this stage through comparatively lower conceptual values for estradiol, epithelial integrity, lubrication, and *Lactobacillus* predominance, together with higher FSH and vaginal pH trends. However, these changes should not be interpreted as universal findings in all postmenopausal women. Hormonal status, sexual activity, local treatments, individual microbial characteristics, and other clinical factors may influence the degree to which these alterations are expressed [4], [11], [20].

Importantly, the biological changes represented in Figure 1 provide a physiological context for understanding menopausal vulvar symptoms but do not independently explain the development of every vulvar dermatosis. Chronic inflammatory conditions such as lichen sclerosus and erosive lichen planus involve distinct pathological mechanisms that cannot be attributed exclusively to estrogen deficiency. Nevertheless, hormonal tissue changes may coexist with these disorders and complicate their clinical presentation, particularly when dryness, irritation, and epithelial fragility occur alongside inflammatory lesions [5], [13], [14], [18].

From a diagnostic perspective, the figure emphasizes the importance of distinguishing generalized estrogen-deficiency-related tissue changes from characteristic morphological abnormalities associated with independent dermatological conditions. Although reduced lubrication and epithelial fragility may support the clinical identification of genitourinary syndrome of menopause, persistent white plaques, erosions, architectural distortion, or localized inflammatory lesions require additional assessment. This distinction is essential because hormonal treatment may improve symptoms associated with estrogen deficiency without adequately addressing a coexisting inflammatory disease [1], [6], [12].

Figure 2.

Reported Prevalence of Genitourinary Syndrome of Menopause Across International and Latin American Evidence

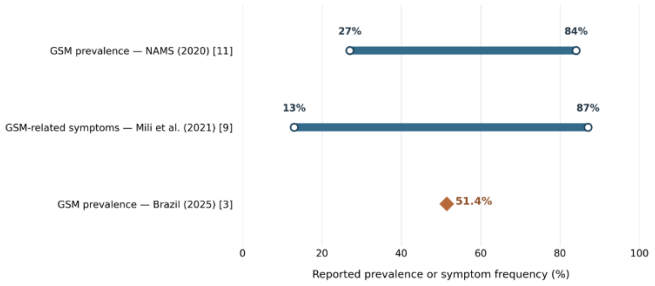

Figure 2 presents a comparative synthesis of epidemiological findings concerning the prevalence of genitourinary syndrome of menopause (GSM) across international and Latin American populations. The graphical representation highlights the considerable variability in reported prevalence estimates and emphasizes the influence of methodological, demographic, and clinical factors on the identification of menopausal genitourinary symptoms. The figure integrates findings from international scientific reviews, professional recommendations, and population-based research conducted in Brazil, providing a broader perspective on the epidemiological characteristics of GSM and its relevance to women's health during the menopausal transition [3], [9], [11].

One of the most relevant findings illustrated in Figure 2 is the substantial variation in the reported prevalence of GSM across international investigations. The North American Menopause Society identified estimates ranging from approximately 27% to 84%, reflecting differences in study populations, diagnostic criteria, and methods used to evaluate genitourinary manifestations. This variability demonstrates that GSM cannot be adequately characterized through a single prevalence estimate applicable to all menopausal populations. Instead, its epidemiological distribution must be interpreted according to the specific characteristics of each investigation, including menopausal status, age distribution, symptom definitions, and clinical assessment procedures [11].

Issue 4, Year 2, Volume 1, No. 02, July-December 2026
E-ISSN: 3122-3591, P-ISSN: 3122-3753
Review International Science Journal

Similarly, the systematic review conducted by Mili et al. identified considerable heterogeneity in the frequency of menopausal genitourinary manifestations. Reported symptom frequencies varied substantially across the included studies, with differences associated with the evaluation of vaginal dryness, irritation, sexual discomfort, and urinary symptoms. These findings emphasize the distinction between the prevalence of GSM as a clinical syndrome and the frequency of individual manifestations. Although both measurements contribute to understanding the burden of menopausal genital health problems, they should not be interpreted as equivalent epidemiological indicators [9].

The Latin American evidence represented in Figure 2 provides an important geographical perspective. The population-based study conducted by Bevilacqua et al. among middle-aged Brazilian women reported a GSM prevalence of approximately 51.4%, indicating that genitourinary manifestations constitute a substantial health concern within the evaluated population. This estimate falls within the broad range described in international literature, supporting the relevance of GSM beyond populations traditionally represented in North American and European investigations. Nevertheless, the Brazilian findings reflect the characteristics of the specific study population and should not be generalized automatically to other Latin American countries [3].

The comparison between international prevalence ranges and the Brazilian estimate also demonstrates the importance of distinguishing population-specific findings from broader epidemiological summaries. International reviews frequently integrate studies involving different age groups, menopausal stages, clinical settings, and assessment instruments. In contrast, population-based investigations provide estimates derived from more clearly defined geographical and demographic groups. Consequently, apparent differences between prevalence estimates may reflect methodological variation rather than genuine biological differences between populations [3], [9], [11].

Another relevant consideration is the influence of menopausal stage on the clinical expression of GSM. Women in perimenopause may experience fluctuating estrogen concentrations and intermittent symptoms, whereas postmenopausal women may develop more persistent manifestations associated with sustained estrogen deficiency. However, symptom severity does not necessarily correspond directly to chronological age or menopausal duration. Individual differences in hormonal exposure, tissue sensitivity, sexual activity, previous treatments, and associated medical conditions may contribute to the variability observed across epidemiological investigations [4], [7], [16].

The epidemiological findings also underscore the importance of symptom recognition and communication within healthcare settings. Genital dryness, burning, dyspareunia, and urinary discomfort may be underreported because of embarrassment, normalization of symptoms as inevitable consequences of aging, or limited opportunities to discuss sexual and genital health during routine consultations. These circumstances can influence the identification of affected individuals and contribute to differences between symptom-based surveys and clinically established diagnoses. Therefore, reported prevalence estimates should be interpreted in the context of the instruments and clinical procedures used to identify GSM [3], [11], [16].

Furthermore, the presence of overlapping vulvar disorders may influence epidemiological classification. Symptoms commonly associated with GSM, including pruritus, irritation, burning, and dyspareunia, may also occur in lichen sclerosus, contact dermatitis, erosive lichen planus, and other inflammatory conditions. When epidemiological studies rely primarily on self-reported symptoms without detailed vulvar examination, some manifestations may be attributed to estrogen deficiency despite the possible coexistence of independent dermatological diseases. This diagnostic overlap represents an important consideration when comparing symptom prevalence across different populations [1], [6], [10], [18].

The figure also highlights the limitations of interpreting broad prevalence ranges as direct indicators of differences in disease severity. A population reporting a higher frequency of genital symptoms does not necessarily exhibit more severe epithelial alterations or a greater burden of inflammatory vulvar disease. Differences in symptom definitions, questionnaires, recall periods, and healthcare-seeking behaviors may substantially influence reported frequencies. Accordingly, epidemiological comparisons require careful consideration of how GSM was defined and measured in each study [9], [11].

From a regional perspective, the Brazilian investigation contributes valuable information to the understanding of menopausal genitourinary health in Latin America. Nevertheless, the available evidence remains insufficient to characterize the full diversity of the region. Differences in socioeconomic conditions, access to gynecological services, educational opportunities, and cultural attitudes toward menopause may influence symptom recognition and clinical evaluation. These factors represent relevant considerations for future epidemiological investigations, although their specific contributions cannot be quantified from the selected evidence alone [3].

The findings summarized in Figure 2 also demonstrate the importance of incorporating standardized diagnostic criteria into future research. Consistent definitions of GSM, clear differentiation between individual symptoms and clinically established syndromes, and systematic assessment of coexisting vulvar dermatoses would improve comparability across populations. Longitudinal studies could additionally clarify how symptom prevalence and clinical

Issue 4, Year 2, Volume 1, No. 02, July-December 2026
E-ISSN: 3122-3591, P-ISSN: 3122-3753
Review International Science Journal

manifestations evolve from perimenopause to established postmenopause, providing more precise information regarding the natural history of menopausal genital changes [4], [9], [11].

Overall, Figure 2 demonstrates that GSM represents a frequent but epidemiologically heterogeneous condition whose reported prevalence depends on population characteristics, diagnostic definitions, and methods of clinical assessment. The integration of international evidence with findings from Brazil supports the global relevance of menopausal genitourinary health while identifying important limitations in the geographical distribution and methodological consistency of existing research. These observations reinforce the need for standardized epidemiological investigations, comprehensive clinical assessment, and greater representation of Latin American populations in future studies [3], [9], [11].

Figure 3.

Comparative Clinical Features of Major Vulvar Dermatoses During the Menopausal Transition

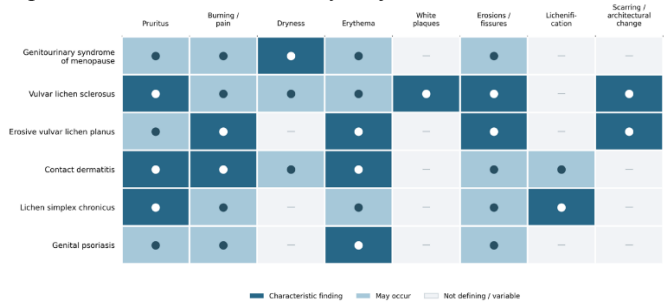

Figure 3 presents a comparative analysis of the principal clinical manifestations associated with genitourinary syndrome of menopause (GSM), vulvar lichen sclerosus, erosive lichen planus, contact dermatitis, lichen simplex chronicus, and genital psoriasis. The comparative matrix integrates eight relevant clinical characteristics: pruritus, burning or pain, dryness, erythema, white plaques, erosions or fissures, lichenification, and scarring or architectural changes. These manifestations are classified according to their characteristic association with each condition, their possible occurrence, or their limited diagnostic relevance. The figure provides a qualitative synthesis of the reviewed literature rather than numerical estimates of symptom prevalence, allowing the identification of overlapping manifestations and distinctive morphological patterns that may contribute to differential diagnosis [1], [6], [10], [19].

One of the principal findings illustrated in Figure 3 is the considerable overlap in subjective symptoms among vulvar disorders. Pruritus, burning, irritation, and discomfort may occur in both estrogen-deficiency-related conditions and chronic inflammatory dermatoses, limiting their usefulness as isolated diagnostic indicators. Raef and Elmariah emphasized the heterogeneous mechanisms underlying vulvar pruritus, including inflammatory, infectious, neuropathic, and irritant processes. Consequently, the presence of itching does not establish a specific diagnosis, and its interpretation requires consideration of associated lesions, anatomical distribution, symptom duration, and potential triggering factors [10].

In the case of GSM, the comparative matrix highlights dryness, burning, and discomfort as clinically relevant manifestations associated with estrogen deficiency. Reduced epithelial maturation, diminished lubrication, and increased tissue fragility contribute to the development of these symptoms, particularly during postmenopause. Erythema and superficial irritation may also occur, although the presence of marked inflammatory plaques or progressive architectural distortion should prompt consideration of an additional diagnosis. These observations are consistent with the clinical descriptions presented by the North American Menopause Society and contemporary reviews addressing the vulvar manifestations of menopausal hormonal changes [4], [11], [17].

The distinction between GSM and lichen sclerosus is particularly important because both conditions frequently affect women during later reproductive aging and may produce similar complaints. However, lichen sclerosus is characterized by distinctive morphological findings, particularly porcelain-white or sclerotic plaques, epidermal fragility, fissuring, and progressive alterations in vulvar architecture. These manifestations reflect a chronic inflammatory process that differs fundamentally from uncomplicated estrogen-deficiency-related epithelial changes. De Luca et al. and Krapf et al. emphasized that characteristic lesions and anatomical changes constitute important clinical indicators of lichen sclerosus, supporting the diagnostic relevance of morphological examination [5], [13].

The matrix also identifies scarring and architectural distortion as particularly relevant features of advanced lichen sclerosus. Chronic inflammation may result in labial resorption, clitoral hood adhesions, and narrowing of the vaginal introitus, potentially producing persistent functional impairment. These changes are clinically significant because they may be irreversible when diagnosis and treatment are delayed. Furthermore, lichen sclerosus is associated with an increased risk of vulvar squamous cell carcinoma, making the recognition of persistent focal abnormalities essential

Issue 4, Year 2, Volume 1, No. 02, July-December 2026
E-ISSN: 3122-3591, P-ISSN: 3122-3753
Review International Science Journal

for appropriate surveillance. The presence of progressive anatomical changes therefore represents an important reason to investigate beyond the diagnosis of GSM [5], [12], [13], [15].

Erosive lichen planus demonstrates a different clinical pattern, with burning, pain, erythema, and erosive lesions representing particularly important manifestations. Unlike lichen sclerosus, which frequently presents with white sclerotic plaques, erosive lichen planus may predominantly involve inflamed mucosal surfaces and persistent erosions. Patients may experience substantial dyspareunia and discomfort, especially when vaginal involvement is present. Chronic disease may also produce adhesions and scarring, emphasizing the importance of distinguishing this condition from isolated menopausal atrophy. Dunaway et al. described the complexity of erosive vulvovaginal lichen planus and the need for targeted treatment in patients with persistent inflammatory manifestations [14].

The comparison of lichen sclerosus and erosive lichen planus demonstrates that the presence of chronic inflammation alone is insufficient for establishing a definitive diagnosis. Both conditions may produce pain, epithelial damage, and anatomical alterations, but their characteristic lesion patterns and distribution differ. Lichen sclerosus commonly affects vulvar and perianal skin, whereas erosive lichen planus may involve vulvar and vaginal mucosal surfaces. These distinctions are particularly relevant because vaginal involvement is unusual in lichen sclerosus but may be prominent in erosive lichen planus. Accordingly, careful assessment of lesion morphology and anatomical distribution can provide valuable diagnostic information [5], [13], [14], [19].

Contact dermatitis represents another important source of vulvar symptoms during the menopausal transition. The figure identifies erythema, pruritus, burning, and irritation as relevant manifestations, while erosions or fissures may develop in more severe presentations. Unlike autoimmune vulvar dermatoses, contact dermatitis is frequently associated with exposure to irritant substances or allergens, including hygiene products, fragrances, topical medications, and other external agents. Geisler and Willems emphasized the importance of identifying relevant exposures and differentiating irritant from allergic mechanisms. This distinction is clinically important because effective management requires removal of the causative exposure in addition to appropriate treatment of cutaneous inflammation [2].

The menopausal transition may complicate the presentation of contact dermatitis because estrogen-deficiency-related epithelial changes can increase tissue sensitivity to friction and external irritants. Consequently, a patient may experience simultaneous GSM and contact dermatitis, producing persistent symptoms that do not respond adequately to hormonal therapy alone. This interaction reinforces the importance of obtaining a detailed history of topical product use, personal hygiene practices, previous treatments, and symptom fluctuations. Clinical evaluation should therefore consider both endogenous physiological changes and external environmental factors [1], [2], [17].

Lichen simplex chronicus demonstrates a characteristic association with chronic pruritus and lichenification. Repetitive scratching or rubbing produces epidermal thickening, accentuation of skin markings, and persistent irritation, establishing an itch–scratch cycle that may perpetuate symptoms even after the initial triggering factor has diminished. The comparative matrix highlights lichenification as a distinguishing feature, although similar changes may occasionally develop secondary to other chronic pruritic disorders. This observation emphasizes that lichen simplex chronicus may represent a primary clinical condition or a secondary response to persistent irritation caused by another vulvar disease [10], [19].

Genital psoriasis presents a different inflammatory pattern, frequently characterized by well-demarcated erythematous plaques. Unlike psoriasis affecting other anatomical regions, genital lesions may demonstrate minimal scaling because of moisture, friction, and the characteristics of intertriginous skin. Pruritus, burning, and discomfort may occur, while extensive scarring and progressive anatomical distortion are not defining characteristics. The identification of psoriasis in other body regions, including the scalp, elbows, knees, or intergluteal area, may support diagnostic assessment. Nevertheless, isolated genital psoriasis can occur and may require differentiation from dermatitis and other inflammatory vulvar conditions [19].

An important aspect of Figure 3 is the distinction between subjective symptoms and objective morphological findings. Subjective manifestations, including pruritus and burning, provide valuable information regarding symptom burden but demonstrate limited specificity. In contrast, findings such as white sclerotic plaques, persistent erosions, lichenification, and progressive architectural changes offer more focused diagnostic clues. However, no individual morphological feature should be considered universally diagnostic, and clinical interpretation must account for disease stage, previous treatment, and overlapping conditions [6], [12], [18].

The figure also demonstrates that clinical characteristics may evolve over time. Early inflammatory dermatoses may present with nonspecific irritation or erythema before developing more recognizable morphological changes. Conversely, previously treated disease may exhibit reduced inflammation while leaving residual anatomical alterations. This variability highlights the importance of longitudinal assessment and reassessment when symptoms persist despite apparently appropriate treatment. In selected cases, histopathological examination may be required to clarify the diagnosis or exclude neoplastic disease [5], [12], [13].

Issue 4, Year 2, Volume 1, No. 02, July-December 2026
E-ISSN: 3122-3591, P-ISSN: 3122-3753
Review International Science Journal

From a therapeutic perspective, the differences illustrated in Figure 3 have important implications for treatment selection. Symptoms associated primarily with GSM may improve with local estrogen therapy and supportive interventions, whereas inflammatory conditions such as lichen sclerosus and erosive lichen planus require disease-specific anti-inflammatory treatment. Similarly, contact dermatitis requires identification and avoidance of relevant exposures, while lichen simplex chronicus management must address the persistent itch–scratch cycle. These distinctions demonstrate why treatment based exclusively on symptom similarity may be inadequate [1], [2], [11], [13], [14].

The comparative findings also support the importance of multidisciplinary clinical evaluation. Gynecological assessment is essential for identifying menopausal genital changes and associated sexual or urinary symptoms, while dermatological expertise may be particularly valuable when characteristic inflammatory lesions, diagnostic uncertainty, or treatment-resistant manifestations are present. Collaboration between specialties can facilitate recognition of coexisting conditions and support individualized management strategies [1], [12], [16].

It is important to recognize that the classifications presented in Figure 3 represent qualitative clinical associations derived from the selected literature. They do not indicate the percentage of patients experiencing each manifestation, establish diagnostic sensitivity or specificity, or represent a validated clinical scoring system. The presence or absence of a characteristic feature should therefore be interpreted within the broader clinical context rather than as an isolated diagnostic criterion.

Overall, Figure 3 demonstrates that the differential diagnosis of vulvar dermatoses during the menopausal transition depends on recognizing both shared symptoms and disease-specific morphological characteristics. While pruritus, burning, dryness, and discomfort may occur across multiple conditions, the identification of sclerotic plaques, erosive mucosal lesions, lichenification, and architectural changes provides clinically relevant information for distinguishing hormonal alterations from inflammatory and autoimmune diseases. This comparative synthesis reinforces the importance of comprehensive vulvar examination, appropriate diagnostic investigations, and individualized therapeutic management in peri- and postmenopausal women [1], [5], [10], [12], [18], [19].

Figure 4.
Diagnostic Pathway for Vulvar Symptoms During the Menopausal Transition

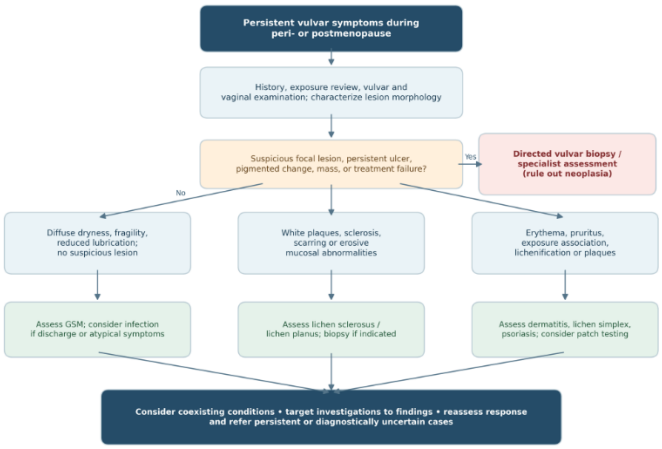

Figure 4 illustrates an integrated diagnostic pathway for evaluating vulvar symptoms during the menopausal transition, emphasizing the importance of differentiating estrogen-deficiency-related manifestations from inflammatory, autoimmune, infectious, and potentially neoplastic conditions. The proposed framework organizes the clinical assessment into sequential stages involving comprehensive history-taking, morphological examination, identification of suspicious lesions, differential diagnosis, complementary investigations, and individualized therapeutic decision-making. This approach reflects the recommendations described in contemporary literature and professional guidelines, which emphasize that persistent vulvar symptoms should not automatically be attributed to menopausal hormonal changes [1], [6], [12], [18].

The initial stage of the diagnostic pathway focuses on identifying the principal symptoms and establishing their clinical characteristics. Vulvar pruritus, burning, dryness, irritation, dyspareunia, and localized pain represent common reasons for consultation among peri- and postmenopausal women. However, these manifestations are not specific to a single pathological process. Raef and Elmariah described vulvar pruritus as a multifactorial symptom associated with

Issue 4, Year 2, Volume 1, No. 02, July-December 2026
E-ISSN: 3122-3591, P-ISSN: 3122-3753
Review International Science Journal

inflammatory dermatoses, infections, irritant exposure, neuropathic mechanisms, and other clinical conditions. Consequently, the diagnostic process must begin with a comprehensive assessment rather than immediate attribution of symptoms to estrogen deficiency [6], [10].

A detailed clinical history constitutes a fundamental component of the initial evaluation. Relevant information includes the duration and progression of symptoms, relationship with sexual activity, previous therapeutic interventions, personal hygiene practices, use of topical medications, and exposure to potential irritants or allergens. The clinician should also investigate associated urinary symptoms, vaginal discomfort, previous dermatological diagnoses, and systemic conditions that may influence genital health. Geisler and Willems emphasized the importance of exposure history in evaluating vulvar dermatitis, particularly when symptoms are recurrent or persist despite conventional treatment [2].

The menopausal context must also be considered during clinical assessment. Changes in menstrual patterns, vasomotor symptoms, previous hormonal treatments, and the duration of menopause may provide information regarding the patient's endocrine status. Nevertheless, menopausal stage alone cannot establish the cause of vulvar symptoms. Although estrogen deficiency contributes to epithelial fragility and reduced lubrication, independent inflammatory diseases may develop before, during, or after menopause. Therefore, hormonal history should be interpreted as one component of a broader diagnostic assessment [4], [7], [17].

Following history-taking, the diagnostic pathway emphasizes direct examination of the vulvar and adjacent genital structures. Inspection should assess epithelial coloration, tissue integrity, lesion distribution, pigmentation, fissures, erosions, plaques, and anatomical configuration. Particular attention should be given to the labia majora, labia minora, clitoral hood, vestibule, perineum, and perianal region. When clinically indicated, vaginal examination may provide additional information regarding mucosal involvement and associated genitourinary manifestations. The American College of Obstetricians and Gynecologists emphasizes the importance of careful morphological evaluation when diagnosing vulvar skin disorders [12].

One of the most important decision points represented in Figure 4 is the identification of suspicious focal lesions or progressive anatomical abnormalities. Persistent ulceration, focal hyperkeratosis, unexplained pigmentation, induration, abnormal vascularity, or lesions that fail to respond to appropriate treatment may require histopathological evaluation. These findings are particularly relevant because chronic inflammatory disorders, especially lichen sclerosus, may coexist with vulvar intraepithelial neoplasia or invasive squamous cell carcinoma. Accordingly, the diagnostic pathway prioritizes the exclusion of potentially malignant abnormalities before attributing persistent symptoms to benign menopausal changes [5], [12], [13].

The role of vulvar biopsy must be interpreted according to the clinical presentation. Histopathological examination may be indicated when the diagnosis is uncertain, lesions demonstrate atypical characteristics, or treatment-resistant abnormalities raise concern for alternative pathology. However, biopsy is not universally required for every patient presenting with typical manifestations of genitourinary syndrome of menopause or clinically recognizable benign inflammatory disease. Instead, its use should be guided by diagnostic uncertainty, lesion characteristics, and the possibility of neoplastic transformation [5], [12], [15].

When suspicious lesions are not identified, the pathway proceeds toward differentiation among the principal hormonal and dermatological conditions. Generalized dryness, epithelial fragility, reduced lubrication, and associated urinary or sexual symptoms may support the clinical identification of genitourinary syndrome of menopause. These manifestations reflect changes in estrogen-responsive tissues and may occur without the distinctive plaques, erosions, or architectural alterations associated with inflammatory vulvar dermatoses. Nevertheless, the presence of GSM does not exclude an additional dermatological diagnosis [4], [9], [11].

The distinction between GSM and lichen sclerosus represents a central component of the diagnostic pathway. Lichen sclerosus frequently presents with porcelain-white plaques, epidermal fragility, fissuring, and progressive alterations in vulvar architecture. Chronic disease may produce labial resorption, clitoral hood adhesions, and introital narrowing. These findings are not typical consequences of uncomplicated estrogen deficiency and should prompt consideration of an inflammatory dermatosis requiring specific treatment and longitudinal surveillance. Contemporary reviews consistently emphasize the importance of recognizing these morphological characteristics to prevent diagnostic delays and disease-related complications [5], [13], [15].

Erosive lichen planus constitutes another important diagnostic consideration, particularly when patients present with persistent burning, pain, erythema, and mucosal erosions. Unlike lichen sclerosus, erosive lichen planus may involve vaginal mucosal surfaces and produce inflammatory adhesions or scarring. The presence of vaginal involvement, painful erosions, and associated oral mucosal lesions may provide additional diagnostic clues. Dunaway et al. highlighted the clinical complexity of erosive vulvovaginal lichen planus, reinforcing the importance of recognizing its distinctive manifestations and differentiating it from estrogen-deficiency-related atrophy [14].

Issue 4, Year 2, Volume 1, No. 02, July-December 2026
E-ISSN: 3122-3591, P-ISSN: 3122-3753
Review International Science Journal

The pathway also incorporates the evaluation of contact dermatitis, lichen simplex chronicus, and genital psoriasis. Contact dermatitis should be considered when symptoms are associated with exposure to topical products, hygiene substances, medications, or other potential irritants and allergens. Lichen simplex chronicus is particularly relevant in patients with persistent pruritus accompanied by lichenification and evidence of repetitive scratching. Genital psoriasis may be suspected when well-demarcated erythematous plaques are present, especially in individuals with psoriasis affecting other anatomical regions. These conditions require different therapeutic approaches despite sharing symptoms such as itching, burning, and irritation [2], [10], [19].

Complementary investigations should be selected according to the clinical findings rather than performed indiscriminately. Microbiological testing may be appropriate when vaginal discharge, odor, acute inflammation, or other manifestations suggest an infectious process. Patch testing may be considered in patients with suspected allergic contact dermatitis, particularly when symptoms persist despite avoidance of common irritants. Histopathological examination may be necessary when lesion morphology is atypical or when the differential diagnosis includes inflammatory or neoplastic conditions that cannot be adequately distinguished through clinical examination alone [2], [6], [12].

An important feature of Figure 4 is the recognition that multiple pathological mechanisms may coexist. For example, a postmenopausal woman may present with estrogen-deficiency-related dryness and simultaneous lichen sclerosus, resulting in persistent discomfort despite appropriate local hormonal therapy. Similarly, contact dermatitis may complicate GSM because fragile epithelial tissues can become more susceptible to irritation from external products. These combined presentations demonstrate that clinical improvement following treatment of one condition does not necessarily exclude the presence of another disorder [1], [4], [18].

The diagnostic pathway therefore incorporates clinical reassessment as a fundamental component of comprehensive management. Patients with persistent symptoms, incomplete therapeutic response, or progressive morphological abnormalities require reconsideration of the initial diagnosis. Reassessment may identify previously unrecognized inflammatory disease, ongoing exposure to irritants, superimposed infection, or the need for additional diagnostic investigations. This approach is particularly important in chronic vulvar disorders, where clinical manifestations may evolve and treatment requirements may change over time [5], [6], [12].

The integration of diagnostic findings with therapeutic decision-making represents another relevant component of the framework. Once the predominant pathological mechanism has been identified, treatment can be directed toward the underlying condition. Genitourinary syndrome of menopause may be managed through appropriate hormonal and nonhormonal interventions, whereas lichen sclerosus and other inflammatory dermatoses require disease-specific anti-inflammatory treatment. Persistent erosive disease, atypical lesions, or complex presentations may justify referral to dermatology, gynecology, or specialized vulvar services [1], [11], [13], [14].

From a clinical perspective, the pathway emphasizes the importance of avoiding therapeutic decisions based exclusively on age or menopausal status. Although estrogen deficiency is common during postmenopause, the assumption that all vulvar symptoms originate from hormonal atrophy may delay recognition of chronic inflammatory disease. Lewis specifically emphasized that postmenopausal vulvar symptoms should not invariably be interpreted as atrophic changes. This observation supports the central diagnostic principle represented in Figure 4: menopausal physiology must be considered alongside, rather than in place of, dermatological examination [18].

The proposed framework also has potential relevance for healthcare settings where access to specialized vulvar services is limited. A structured approach based on clinical history, lesion morphology, recognition of warning signs, and appropriate referral may help organize initial assessment and identify patients requiring additional evaluation. Nevertheless, the pathway has not undergone prospective validation, and its diagnostic accuracy cannot be established from the present narrative review. Its application should therefore remain dependent on professional clinical judgment and established diagnostic recommendations [1], [12].

Figure 5.
Evidence-Based Therapeutic Approaches for Vulvar Dermatoses During the Menopausal Transition

Issue 4, Year 2, Volume 1, No. 02, July-December 2026
E-ISSN: 3122-3591, P-ISSN: 3122-3753
Review International Science Journal

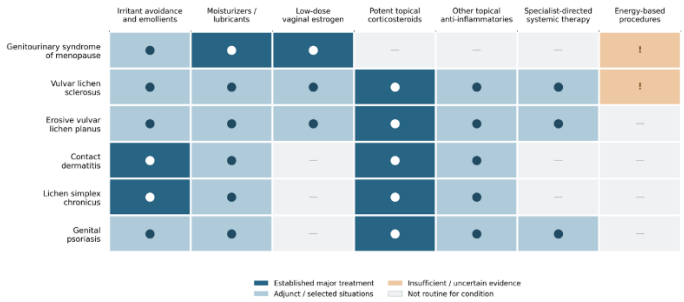

Figure 5 presents a comparative synthesis of therapeutic strategies for the principal vulvar disorders encountered during the menopausal transition, emphasizing the importance of selecting interventions according to the underlying pathological mechanism. The matrix integrates six clinical conditions—genitourinary syndrome of menopause (GSM), vulvar lichen sclerosus, erosive lichen planus, contact dermatitis, lichen simplex chronicus, and genital psoriasis—and seven therapeutic categories, including irritant avoidance and emollients, moisturizers and lubricants, low-dose vaginal estrogen, potent topical corticosteroids, other topical anti-inflammatory agents, specialist-directed systemic therapy, and energy-based procedures. The figure distinguishes established therapeutic indications from supportive interventions and approaches for which evidence remains limited or uncertain. This classification provides a qualitative representation of the reviewed literature rather than a quantitative comparison of treatment effectiveness [1], [8], [11], [12].

One of the principal findings illustrated in Figure 5 is that vulvar disorders occurring during menopause cannot be managed through a uniform therapeutic approach. Although several conditions share symptoms such as pruritus, burning, dryness, and dyspareunia, their underlying biological mechanisms differ substantially. Estrogen deficiency contributes to epithelial thinning, reduced lubrication, and genitourinary discomfort, whereas inflammatory and autoimmune dermatoses involve pathological processes requiring targeted anti-inflammatory treatment. Consequently, therapeutic selection should be based on clinical diagnosis rather than symptom similarity alone. This distinction is particularly relevant in postmenopausal women, among whom hormonal tissue changes may coexist with independent dermatological diseases [1], [4], [18].

For GSM, the figure identifies nonhormonal moisturizers, lubricants, and local hormonal therapy as relevant therapeutic options. Vaginal moisturizers may provide relief from persistent dryness, while lubricants are particularly useful for reducing friction-related discomfort during sexual activity. These interventions can be appropriate for women with mild symptoms, those who prefer nonhormonal management, or individuals for whom hormonal treatment is unsuitable. However, their effects are primarily symptomatic, and they do not necessarily reproduce the broader epithelial changes associated with estrogenic stimulation. The North American Menopause Society recognizes nonhormonal approaches as important components of individualized GSM management [9], [11].

Low-dose vaginal estrogen represents an established treatment for persistent moderate-to-severe GSM symptoms. By acting on estrogen-responsive tissues, local estrogen therapy can improve epithelial maturation, tissue hydration, vaginal lubrication, and certain manifestations of genitourinary discomfort. Available formulations include vaginal creams, tablets, inserts, and rings, allowing treatment selection according to patient preferences, clinical characteristics, and product availability. Nevertheless, treatment decisions should consider relevant contraindications, individual risk factors, and the need for additional specialist assessment in selected patients [4], [11], [17].

An important therapeutic distinction concerns the limited role of estrogen replacement in primary inflammatory vulvar dermatoses. Although local estrogen therapy may improve coexisting GSM, it does not constitute disease-modifying treatment for lichen sclerosus, erosive lichen planus, or other independent inflammatory conditions. Therefore, persistent pruritus, plaques, erosions, or architectural changes despite adequate estrogen therapy should prompt reassessment rather than automatic intensification of hormonal treatment. This observation reinforces the need to recognize combined hormonal and dermatological pathology during menopause [1], [5], [13], [18].

The therapeutic management of vulvar lichen sclerosus represents one of the clearest examples of condition-specific treatment. Contemporary scientific reviews and professional recommendations consistently identify potent or ultrapotent topical corticosteroids as the principal first-line intervention. Clobetasol propionate 0.05% is widely used to control inflammation, reduce symptoms, and limit disease progression. Treatment generally requires an initial therapeutic phase followed by individualized maintenance according to clinical response and disease activity. Appropriate instruction regarding medication application and adherence is essential to achieving adequate disease control [5], [12], [13].

The importance of corticosteroid treatment in lichen sclerosus extends beyond the reduction of pruritus and discomfort. Persistent inflammation may contribute to progressive scarring, anatomical distortion, and complications associated

Issue 4, Year 2, Volume 1, No. 02, July-December 2026
E-ISSN: 3122-3591, P-ISSN: 3122-3753
Review International Science Journal

with chronic disease. Long-term surveillance is therefore necessary to evaluate inflammatory activity, identify treatment-related concerns, and detect suspicious lesions requiring histopathological assessment. Although appropriate treatment may reduce the likelihood of disease progression, previously established anatomical changes may not be completely reversible. These considerations emphasize the importance of early diagnosis and sustained clinical follow-up [5], [13], [15].

Erosive vulvar lichen planus presents additional therapeutic challenges because of its chronic inflammatory nature and potential involvement of mucosal surfaces. The figure identifies potent topical corticosteroids and other anti-inflammatory agents as relevant therapeutic approaches, while specialist-directed systemic treatment may be necessary in selected refractory cases. Dunaway et al. described the complexity of managing erosive vulvovaginal lichen planus, particularly when persistent inflammation, pain, and scarring interfere with daily activities and sexual function. Treatment must therefore be individualized according to disease severity, anatomical involvement, previous therapeutic response, and potential adverse effects [14].

Topical calcineurin inhibitors and other anti-inflammatory treatments may be considered in selected inflammatory vulvar disorders when conventional corticosteroid therapy is insufficient, poorly tolerated, or unsuitable for prolonged use. However, their indications vary among conditions, and the strength of supporting evidence is not uniform. In refractory disease, systemic immunomodulatory therapies may be considered under specialist supervision. These interventions require careful assessment of potential benefits, adverse effects, and monitoring requirements. Consequently, the matrix identifies specialist-directed systemic therapy as a selective rather than universal therapeutic strategy [5], [14], [19].

Contact dermatitis demonstrates a different therapeutic priority because successful management depends substantially on identifying and eliminating relevant irritant or allergenic exposures. Common contributing factors may include fragranced hygiene products, topical preparations, sanitary materials, and other substances that come into contact with vulvar skin. Geisler and Willems emphasized the importance of exposure identification and avoidance as central components of management. Supportive barrier protection and appropriately selected topical corticosteroids may be useful for controlling inflammation, but sustained improvement often requires modification of the triggering exposure [2].

The figure also highlights the role of emollients and gentle vulvar care across multiple conditions. Avoidance of unnecessary cleansing products, reduction of excessive friction, and maintenance of an appropriate skin barrier may reduce irritation and improve tolerability of disease-specific treatments. Nevertheless, supportive interventions should not be interpreted as substitutes for established therapies in conditions such as lichen sclerosus or erosive lichen planus. Their principal role is complementary, particularly when epithelial fragility or exposure-related irritation contributes to persistent discomfort [1], [2], [10].

Lichen simplex chronicus requires a therapeutic strategy directed toward interrupting the persistent itch–scratch cycle. Repetitive scratching promotes epidermal thickening, increased sensitivity, and continued pruritus, creating a self-perpetuating inflammatory process. Appropriate topical anti-inflammatory treatment, avoidance of aggravating factors, and identification of underlying causes of itching constitute important components of management. When lichen simplex chronicus develops secondary to another vulvar condition, effective treatment also requires addressing the primary disorder. This approach reflects the multifactorial nature of chronic vulvar pruritus described in the literature [10], [19].

The management of genital psoriasis requires particular attention to the anatomical characteristics of vulvar skin. Although topical corticosteroids constitute an important treatment option, potency, duration, and application frequency should be individualized because genital and intertriginous surfaces may be more susceptible to treatment-related adverse effects. Other topical anti-inflammatory agents may be considered in selected cases, while systemic therapy is generally reserved for more extensive, severe, or treatment-resistant psoriasis under specialist supervision. The therapeutic classification in Figure 5 therefore reflects the need for condition-specific selection rather than routine use of high-potency corticosteroids across all vulvar inflammatory disorders [12], [19].

An additional consideration is the coexistence of GSM with inflammatory vulvar dermatoses. In such cases, treatment may require simultaneous management of estrogen-deficiency-related symptoms and the independent inflammatory process. For example, a patient with lichen sclerosus and persistent menopausal dryness may benefit from appropriate corticosteroid therapy for inflammatory disease alongside selected interventions directed toward GSM. However, these treatments address different pathological mechanisms and should not be considered interchangeable. Recognizing this distinction may help explain incomplete symptom resolution when only one contributing condition is treated [1], [4], [11], [13].

The figure also incorporates energy-based procedures as a therapeutic category requiring cautious interpretation. Vaginal laser technologies have been investigated for GSM and other genital conditions, with some studies reporting improvements in selected symptoms. Nevertheless, Mortensen et al. identified important limitations in the available

Issue 4, Year 2, Volume 1, No. 02, July-December 2026
E-ISSN: 3122-3591, P-ISSN: 3122-3753
Review International Science Journal

evidence, including heterogeneity in treatment protocols, variability in outcome measurements, and insufficient long-term safety data. These limitations restrict the ability to establish consistent superiority over conventional treatments or recommend routine use for vulvar inflammatory disorders [8].

The distinction between established and emerging therapies is particularly important because improvements in subjective symptoms do not necessarily demonstrate modification of the underlying pathological process. For example, temporary reductions in discomfort following an intervention may not indicate sustained restoration of epithelial function or control of chronic inflammatory disease. Consequently, therapeutic evaluation should consider clinically meaningful outcomes, durability of response, adverse effects, and the quality of supporting evidence. This principle is especially relevant when assessing interventions supported primarily by small or methodologically heterogeneous studies [8], [11].

Long-term clinical follow-up represents another essential component of comprehensive therapeutic management. For GSM, follow-up allows evaluation of symptom relief, treatment tolerability, and the need for adjustment of hormonal or nonhormonal interventions. In chronic inflammatory disorders, particularly lichen sclerosus and erosive lichen planus, reassessment should additionally examine inflammatory activity, tissue integrity, anatomical changes, and persistent or suspicious lesions. These differences demonstrate that follow-up requirements must be adapted to the underlying diagnosis rather than determined exclusively by the presence or absence of symptoms [5], [12], [13], [14].

Patient education and shared decision-making are also important for treatment effectiveness. Women experiencing chronic vulvar symptoms may require guidance regarding the expected duration of treatment, correct application of topical medications, avoidance of aggravating exposures, and indications for further evaluation. Clear communication may improve treatment adherence and reduce unnecessary discontinuation of effective therapies. Furthermore, discussing sexual discomfort and intimate symptoms in a respectful clinical environment can support more comprehensive identification of treatment needs [1], [11], [16].

The interdisciplinary dimension of therapeutic management is particularly relevant in complex or refractory presentations. Gynecological expertise contributes to the evaluation of menopausal endocrine changes and associated genitourinary manifestations, while dermatological assessment is important for inflammatory lesions, diagnostic uncertainty, and treatment-resistant disease. Additional specialist involvement may be required when extensive mucosal disease, significant anatomical changes, or suspected neoplastic lesions are identified. This integrated approach supports individualized management and reduces the risk of treating all menopausal vulvar symptoms as manifestations of estrogen deficiency [1], [5], [12], [14].

It is important to recognize that Figure 5 represents a qualitative synthesis of therapeutic indications rather than a comparative effectiveness analysis. The classifications do not establish numerical treatment success rates, relative risks, or pooled effect sizes. Furthermore, the presence of a therapeutic option within the matrix does not imply that it is appropriate for every patient with the corresponding diagnosis. Treatment selection must account for disease severity, contraindications, previous responses, available resources, and clinical judgment.

Overall, Figure 5 demonstrates that effective management of vulvar dermatoses during the menopausal transition requires differentiation between hormonal, inflammatory, autoimmune, and exposure-related mechanisms. Nonhormonal supportive care and local estrogen therapy remain important for GSM, whereas topical anti-inflammatory treatment constitutes the foundation of management for several chronic inflammatory vulvar disorders. Specialist-directed therapies and emerging interventions require individualized assessment and careful consideration of the available evidence. The principal contribution of the figure is to reinforce a mechanism-based, multidisciplinary, and patient-centered therapeutic approach that prioritizes diagnostic accuracy, appropriate treatment selection, and long-term preservation of vulvar health [1], [5], [8], [11], [12], [13], [14].

DISCUSSION

The findings of this narrative review demonstrate that vulvar dermatoses during the menopausal transition represent a complex clinical spectrum influenced by endocrine alterations, epithelial modifications, inflammatory mechanisms, and individual susceptibility factors. The evidence indicates that declining estrogen concentrations contribute to changes in vulvovaginal tissue integrity, lubrication, local microbial composition, and epithelial resilience. Nevertheless, these physiological alterations do not independently explain the development of all vulvar dermatological disorders. The coexistence of genitourinary syndrome of menopause (GSM) with inflammatory and autoimmune dermatoses represents a particularly important diagnostic challenge because overlapping symptoms may obscure the underlying pathological process and complicate therapeutic decision-making. Consequently, comprehensive evaluation requires an integrated understanding of hormonal physiology and dermatological pathology rather than the assumption that all genital symptoms occurring during menopause are attributable to estrogen deficiency [1], [4], [7], [17].

Issue 4, Year 2, Volume 1, No. 02, July-December 2026
E-ISSN: 3122-3591, P-ISSN: 3122-3753
Review International Science Journal

The hormonal and epithelial relationships illustrated in Figure 1 are consistent with scientific investigations describing the influence of estrogen deficiency on genital tissue physiology. Cucinella et al. emphasized the vulvar component of GSM, highlighting that menopausal manifestations extend beyond vaginal atrophy and involve anatomical structures with distinct epithelial and functional characteristics. Similarly, Hum and Dytoc described the dermatological implications of menopausal genital changes, emphasizing the importance of recognizing vulvar manifestations within a broader clinical assessment. These findings support the interpretation that endocrine alterations provide an important biological context for understanding vulvar symptoms without necessarily constituting the primary cause of every inflammatory or autoimmune condition [4], [17].

The progressive decline in estrogenic stimulation may contribute to reduced epithelial maturation, diminished tissue hydration, and increased susceptibility to mechanical irritation. However, the relationship between circulating hormone concentrations and clinical symptoms is not necessarily linear. Individual differences in tissue responsiveness, local environmental conditions, previous hormonal exposure, and associated medical conditions may influence the intensity of menopausal genital manifestations. Therefore, the conceptual hormonal trends represented in Figure 1 should not be interpreted as universal physiological trajectories or as quantitative predictors of symptom severity. Rather, they illustrate biological relationships that may contribute to the development of GSM and influence the clinical expression of coexisting vulvar disorders [4], [7], [11].

The relationship between menopausal hormonal changes and the vaginal microbiota introduces an additional dimension to the understanding of genital health during reproductive aging. Brotman et al. identified associations between menopausal status, microbial community composition, and signs of vulvovaginal atrophy, suggesting that endocrine alterations may influence the local microbial environment through changes in epithelial maturation and glycogen availability. Nevertheless, these associations do not establish a direct causal relationship between microbiota modifications and the development of autoimmune vulvar dermatoses. The available evidence supports the biological interaction between hormonal status and microbial ecology, but the contribution of these changes to chronic inflammatory disease remains incompletely understood. Future longitudinal investigations incorporating endocrine, microbiological, and dermatological assessments may clarify whether specific microbial patterns influence symptom persistence or inflammatory activity during menopause [20].

The epidemiological findings summarized in Figure 2 reveal considerable variability in the reported prevalence of GSM across international investigations. The North American Menopause Society has described prevalence estimates ranging from approximately 27% to 84%, while systematic reviews have identified substantial differences in the frequency of individual genitourinary symptoms. This heterogeneity reflects variations in study populations, menopausal stages, diagnostic definitions, assessment instruments, and healthcare settings. Consequently, the prevalence of GSM cannot be adequately represented by a single estimate applicable to all populations. The distinction between clinically established GSM and isolated symptoms such as dryness or dyspareunia is particularly important because these outcomes are not epidemiologically equivalent [9], [11].

The population-based investigation conducted by Bevilacqua et al. in Brazil provides an important Latin American contribution to the epidemiological understanding of GSM. The reported prevalence of approximately 51.4% demonstrates that menopausal genitourinary manifestations represent a substantial clinical concern within the evaluated population. Although this estimate falls within the broad range described in international literature, differences in study design and diagnostic criteria prevent direct comparisons without methodological qualification. Furthermore, the Brazilian findings should not be generalized automatically to other Latin American countries, where demographic characteristics, healthcare accessibility, cultural attitudes toward menopause, and clinical assessment practices may differ considerably [3].

An important consideration emerging from the epidemiological evidence is the potential underrecognition of menopausal genital symptoms. Women may avoid discussing vulvar discomfort, sexual pain, or urinary complaints because of embarrassment, limited knowledge regarding available treatments, or the perception that such manifestations are inevitable consequences of aging. These factors may influence symptom reporting and healthcare utilization, potentially contributing to discrepancies between population-based surveys and clinical diagnoses. Although the selected literature supports the relevance of communication barriers in menopausal genital health, the

Issue 4, Year 2, Volume 1, No. 02, July-December 2026
E-ISSN: 3122-3591, P-ISSN: 3122-3753
Review International Science Journal

Issue 4, Year 2, Volume 1, No. 02, July-December 2026
E-ISSN: 3122-3591, P-ISSN: 3122-3753
Review International Science Journal

specific contribution of these factors to prevalence differences cannot be quantified through the present narrative synthesis [3], [11], [16].

The comparative findings presented in Figure 3 demonstrate that the principal symptoms associated with vulvar disorders exhibit limited diagnostic specificity. Pruritus, burning, irritation, and discomfort may occur in GSM, lichen sclerosus, erosive lichen planus, contact dermatitis, lichen simplex chronicus, and genital psoriasis. Raef and Elmariah emphasized the heterogeneous etiologies of vulvar pruritus, including inflammatory, infectious, neuropathic, and irritant mechanisms. Similarly, Lewis highlighted the importance of recognizing that vulvar symptoms after menopause cannot invariably be attributed to atrophic changes. These observations support the conclusion that symptom-based assessment alone is insufficient for establishing an accurate diagnosis [10], [18].

Morphological examination provides additional information that may help differentiate conditions presenting with similar subjective manifestations. The identification of porcelain-white plaques, progressive architectural distortion, persistent erosions, lichenification, or well-demarcated erythematous lesions may suggest specific inflammatory dermatoses. However, these findings must be interpreted according to anatomical distribution, disease duration, previous treatment, and associated clinical characteristics. The comparative matrix developed in Figure 3 therefore offers a structured representation of characteristic clinical patterns without implying that individual manifestations possess established diagnostic sensitivity or specificity [5], [12], [19].

The differentiation between GSM and lichen sclerosus is particularly important because both conditions may affect postmenopausal women but involve fundamentally different pathological mechanisms. GSM is associated with changes in estrogen-responsive tissues, whereas lichen sclerosus is a chronic inflammatory disorder involving immune-mediated processes and other contributing factors. De Luca et al. and Krapf et al. described the characteristic clinical manifestations of lichen sclerosus, including sclerotic plaques, epithelial fragility, fissuring, and progressive anatomical changes. Although menopausal hormonal alterations may influence tissue vulnerability and symptom perception, current evidence does not establish estrogen deficiency as the direct cause of lichen sclerosus [5], [13].

The clinical significance of this distinction extends beyond treatment selection. Persistent inflammation associated with lichen sclerosus may contribute to irreversible architectural changes and is associated with an increased risk of vulvar squamous cell carcinoma. Delayed recognition may therefore have consequences that differ substantially from those associated with uncomplicated GSM. Professional recommendations emphasize appropriate anti-inflammatory treatment, long-term follow-up, and evaluation of suspicious lesions. These considerations support the importance of recognizing characteristic morphological abnormalities and avoiding the assumption that persistent vulvar symptoms necessarily represent physiological menopausal changes [5], [12], [13], [15].

Erosive lichen planus represents another relevant diagnostic challenge because its manifestations may overlap with those of estrogen-deficiency-related mucosal fragility and other inflammatory disorders. Persistent burning, painful erosions, erythema, and mucosal involvement may produce considerable discomfort and functional impairment. Unlike uncomplicated GSM, erosive lichen planus may progress to adhesions and scarring, particularly when vaginal mucosal surfaces are affected. Dunaway et al. described the therapeutic complexity of erosive vulvovaginal lichen planus, emphasizing the need for individualized treatment and specialist assessment in refractory disease. These findings reinforce the importance of distinguishing inflammatory mucosal pathology from hormonal atrophy through careful examination and appropriate diagnostic evaluation [14].

Contact dermatitis, lichen simplex chronicus, and genital psoriasis further demonstrate the diversity of mechanisms underlying vulvar symptoms. Contact dermatitis may arise from irritant exposure or allergic reactions, while lichen simplex chronicus is frequently associated with persistent scratching and disruption of the normal epidermal barrier. Genital psoriasis represents an inflammatory condition whose morphology may differ from psoriasis affecting other anatomical regions because of local moisture and friction. These distinctions indicate that effective diagnosis requires consideration of environmental exposures, behavioral factors, and characteristic lesion patterns rather than relying exclusively on menopausal status [2], [10], [19].

The diagnostic framework presented in Figure 4 integrates these findings into a structured clinical approach. Comprehensive history-taking, direct vulvar examination, identification of suspicious lesions, and targeted

Issue 4, Year 2, Volume 1, No. 02, July-December 2026
E-ISSN: 3122-3591, P-ISSN: 3122-3753
Review International Science Journal

Issue 4, Year 2, Volume 1, No. 02, July-December 2026
E-ISSN: 3122-3591, P-ISSN: 3122-3753
Review International Science Journal

complementary investigations constitute essential components of evaluation. The American College of Obstetricians and Gynecologists emphasizes the importance of morphological assessment and appropriate diagnostic procedures in vulvar skin disorders. Similarly, Mitchell highlighted the need for careful evaluation of persistent vulvovaginal itching in postmenopausal women. Together, these recommendations support a diagnostic strategy that prioritizes identification of the underlying pathological process before therapeutic intervention [6], [12].

Nevertheless, the proposed diagnostic pathway should not be interpreted as a prospectively validated clinical instrument. Its purpose is to organize established assessment principles and facilitate the recognition of relevant differential diagnoses. The pathway does not provide numerical estimates of diagnostic sensitivity, specificity, or predictive accuracy. Furthermore, patients may present with simultaneous GSM, inflammatory dermatoses, infections, or irritant exposure, resulting in clinical patterns that do not correspond to a single diagnostic category. Accordingly, the framework must remain adaptable to individual presentations and should complement professional clinical judgment rather than replace it [1], [6], [12].

The therapeutic synthesis illustrated in Figure 5 demonstrates that treatment selection should be directed toward the underlying pathological mechanism. For GSM, nonhormonal moisturizers, lubricants, and low-dose vaginal estrogen represent established therapeutic options, with selection depending on symptom severity, patient preferences, contraindications, and clinical characteristics. The North American Menopause Society position statement supports individualized management and recognizes the importance of local hormonal therapy for persistent symptomatic disease. However, these interventions primarily address estrogen-deficiency-related manifestations and should not be considered definitive treatment for independent inflammatory or autoimmune vulvar disorders [9], [11].

In contrast, potent or ultrapotent topical corticosteroids constitute the principal therapeutic approach for vulvar lichen sclerosus. Contemporary reviews emphasize their effectiveness in controlling inflammatory activity, reducing symptoms, and limiting disease progression when appropriately prescribed and monitored. This distinction is particularly important when symptoms persist despite local estrogen therapy, as inadequate response may indicate an additional dermatological condition rather than insufficient hormonal treatment. The coexistence of GSM and lichen sclerosus may require simultaneous but mechanistically distinct therapeutic interventions [1], [5], [13].

The management of erosive lichen planus and other persistent inflammatory dermatoses presents additional challenges because the available therapeutic evidence is heterogeneous. Topical anti-inflammatory agents remain important interventions, while specialist-directed systemic therapies may be considered in selected refractory cases. However, differences in disease severity, treatment protocols, and reported outcomes limit the ability to establish universally applicable therapeutic hierarchies. Similar considerations apply to genital psoriasis, where topical treatment must be individualized according to the sensitivity of genital skin and the potential adverse effects associated with prolonged corticosteroid exposure [14], [19].

The role of supportive vulvar care also deserves consideration. Avoidance of irritants, gentle cleansing, appropriate emollient use, and reduction of excessive friction may contribute to symptom control across several conditions. Nevertheless, these interventions should complement rather than replace disease-specific treatment. In contact dermatitis, identification and elimination of relevant exposures are particularly important, whereas lichen simplex chronicus requires interruption of the persistent itch–scratch cycle. These observations reinforce the importance of tailoring therapeutic strategies to the mechanisms responsible for each clinical presentation [1], [2], [10].

Emerging energy-based interventions represent an area of continued scientific uncertainty. Mortensen et al. reviewed the evidence supporting laser-based treatments for GSM, vulvovaginal atrophy, urinary incontinence, and lichen sclerosus, identifying limitations related to study quality, outcome heterogeneity, and long-term safety assessment. Although selected investigations have reported symptomatic improvements, the available evidence does not consistently establish superiority over conventional treatments. Consequently, these procedures should not routinely replace established hormonal or anti-inflammatory therapies, particularly when their long-term benefits and risks remain insufficiently characterized [8].

Another important finding concerns the need for interdisciplinary clinical management. Vulvar symptoms during menopause may involve endocrine changes, dermatological inflammation, sexual discomfort, urinary manifestations,

Issue 4, Year 2, Volume 1, No. 02, July-December 2026
E-ISSN: 3122-3591, P-ISSN: 3122-3753
Review International Science Journal

Issue 4, Year 2, Volume 1, No. 02, July-December 2026
E-ISSN: 3122-3591, P-ISSN: 3122-3753
Review International Science Journal

and psychological consequences. Gynecological assessment contributes to the recognition of menopausal genital changes, while dermatological expertise is particularly valuable when characteristic inflammatory lesions, persistent symptoms, or diagnostic uncertainty are present. Collaboration between specialties may improve recognition of coexisting conditions and facilitate individualized therapeutic decisions. This integrated approach is consistent with contemporary recommendations emphasizing comprehensive management of vulvar disorders [1], [7], [16].

The implications of these findings for Latin American healthcare settings require additional consideration. Although the Brazilian population-based investigation contributes relevant regional evidence, the available literature remains insufficient to characterize the diversity of menopausal vulvar health across Latin America. Differences in access to specialized services, availability of diagnostic procedures, treatment affordability, and cultural perceptions of genital symptoms may influence clinical recognition and management. Nevertheless, the selected publications do not permit quantification of these potential differences. Future multicenter investigations involving geographically and socioeconomically diverse populations are therefore necessary to strengthen the regional applicability of international recommendations [3].

Several methodological limitations must be acknowledged when interpreting the present findings. First, the narrative review design does not incorporate the exhaustive search procedures, formal risk-of-bias assessments, or quantitative synthesis characteristic of systematic reviews. Second, the selected publications differ in population characteristics, diagnostic definitions, study designs, and therapeutic outcomes, limiting direct comparisons. Third, much of the available evidence examines GSM and inflammatory vulvar dermatoses separately, restricting the understanding of their coexistence during the menopausal transition. Finally, the biological relationships between hormonal depletion, local microbial changes, and inflammatory vulvar disease remain incompletely characterized [4], [9], [20].

The figures developed for this review also require appropriate methodological interpretation. Figure 1 represents conceptual hormonal and epithelial trends rather than measured longitudinal values. Figure 2 integrates epidemiological estimates derived from heterogeneous sources without calculating a pooled prevalence. Figures 3 and 5 provide qualitative comparisons of clinical manifestations and therapeutic indications, while Figure 4 presents an evidence-informed diagnostic framework without prospective validation. Consequently, these visual representations should be understood as instruments for organizing and interpreting scientific knowledge rather than as original clinical measurements or experimentally validated models.

Future research should prioritize prospective longitudinal investigations examining vulvar health across clearly defined stages of reproductive aging. Standardized assessment of hormonal status, lesion morphology, symptom severity, microbial composition, and therapeutic outcomes would improve understanding of the relationships between menopausal physiology and inflammatory dermatological disease. Additional studies should evaluate the frequency and clinical consequences of coexisting GSM and vulvar dermatoses, as well as the comparative effectiveness of individualized treatment strategies. Greater representation of Latin American populations would also strengthen the geographical applicability of available evidence.

CONCLUSION

Vulvar dermatoses during the menopausal transition represent a clinically complex group of conditions in which hormonal alterations, epithelial changes, inflammatory mechanisms, and individual susceptibility factors contribute to the development of genital symptoms. The evidence examined in this narrative review demonstrates that declining estrogen concentrations are associated with reduced epithelial maturation, diminished lubrication, increased tissue fragility, and modifications in the vaginal microbial environment. These physiological changes constitute important mechanisms underlying genitourinary syndrome of menopause (GSM); however, they do not adequately explain the development of all vulvar dermatological disorders. Consequently, menopausal status should be considered a relevant clinical factor rather than a sufficient explanation for persistent vulvar symptoms [4], [7], [11], [17], [20].

The comparative analysis of clinical manifestations demonstrates that pruritus, burning, dryness, irritation, and dyspareunia frequently overlap among GSM, lichen sclerosus, erosive lichen planus, contact dermatitis, lichen simplex chronicus, and genital psoriasis. Nevertheless, distinctive morphological characteristics, including sclerotic white plaques, persistent erosions, lichenification, and progressive architectural changes, provide important information for

Issue 4, Year 2, Volume 1, No. 02, July-December 2026
E-ISSN: 3122-3591, P-ISSN: 3122-3753
Review International Science Journal

differential diagnosis. The identification of these findings requires comprehensive clinical history-taking, careful vulvar examination, and selective use of complementary investigations. Persistent, atypical, or treatment-resistant lesions warrant further assessment to exclude alternative inflammatory conditions and potentially neoplastic abnormalities [5], [6], [10], [12], [13], [18], [19].

The epidemiological evidence confirms that GSM is a frequent condition among peri- and postmenopausal women, although reported prevalence varies substantially according to diagnostic definitions, population characteristics, and assessment methods. Findings from Brazil contribute valuable information regarding the burden of menopausal genitourinary manifestations in Latin America, but they cannot be generalized to the entire region without additional population-based investigations. The heterogeneity of existing studies highlights the importance of standardized diagnostic criteria and greater geographical representation in future research [3], [9], [11].

Therapeutic management must be individualized according to the underlying pathological mechanism. Nonhormonal moisturizers, lubricants, and low-dose vaginal estrogen constitute important options for GSM, whereas potent topical corticosteroids remain central to the management of vulvar lichen sclerosus. Other inflammatory conditions require targeted anti-inflammatory treatment, identification of contributing exposures, and specialist-directed interventions when clinically indicated. Supportive vulvar care and patient education should complement disease-specific therapies, while emerging energy-based procedures require cautious consideration because of limitations in the available evidence regarding comparative effectiveness and long-term safety [1], [2], [5], [8], [11], [13], [14].

The coexistence of hormonal changes and independent inflammatory dermatoses reinforces the importance of interdisciplinary collaboration between gynecology and dermatology. An integrated clinical approach can facilitate earlier recognition of characteristic lesions, reduce inappropriate attribution of symptoms to estrogen deficiency, and support treatment strategies that address multiple contributing conditions. Longitudinal follow-up is particularly important in chronic inflammatory diseases associated with progressive anatomical changes or increased neoplastic risk [1], [5], [12], [13], [15].

Finally, this review identifies the need for further prospective research examining the interaction between menopausal endocrine changes, vulvar epithelial physiology, microbial alterations, and chronic inflammatory disease. Standardized diagnostic frameworks, longitudinal clinical assessment, and comparative therapeutic investigations are necessary to strengthen the available evidence. Greater inclusion of Latin American populations would also improve understanding of regional clinical characteristics and healthcare needs. Overall, the findings support a comprehensive, evidence-informed, and patient-centered approach in which accurate differential diagnosis, mechanism-specific treatment, and sustained clinical surveillance constitute the foundations of effective vulvar healthcare during the menopausal transition [1], [3], [4], [11], [12], [20].

REFERENCES

[1] O. Negris, A. Ghafari-Saravi, and M. M. Mauskar, “A practical management approach to vulvar dermatoses and genitourinary syndrome of menopause,” *Obstetrics & Gynecology*, Sep. 2026, doi: **10.1097/AOG.0000000000006422**.
[2] A. N. Geisler and J. J. Willems, “Vulvar dermatitis: Diagnosis and management,” *Clinical Obstetrics and Gynecology*, vol. 69, no. 2, pp. 103–113, 2026, doi: **10.1097/GRF.0000000000001006**.
[3] M. R. R. Bevilacqua, L. Costa-Paiva, and A. O. Pedro, “Prevalence and predictors of genitourinary syndrome of menopause: A population-based study in middle-aged Brazilian women,” *Menopause*, vol. 32, no. 2, pp. 134–141, 2025, doi: **10.1097/GME.0000000000002467**.
[4] L. Cucinella, L. Tiranini, C. Cassani, *et al*., “Insights into the vulvar component of the genitourinary syndrome of menopause (GSM),” *Maturitas*, vol. 186, Art. no. 108006, 2024, doi: **10.1016/j.maturitas.2024.108006**.
[5] D. A. De Luca, C. Papara, A. Vorobyev, *et al*., “Lichen sclerosus: The 2023 update,” *Frontiers in Medicine*, vol. 10, Art. no. 1106318, 2023, doi: **10.3389/fmed.2023.1106318**.
[6] C. Mitchell, “Evaluation and treatment of vulvovaginal itching in postmenopausal women,” *Menopause*, vol. 30, no. 9, pp. 969–971, 2023, doi: **10.1097/GME.0000000000002218**.
[7] E. Musbahi, E. Kamp, M. Ashraf, and C. DeGiovanni, “Menopause, skin and common dermatosis. Part 3: Genital disorders,” *Clinical and Experimental Dermatology*, vol. 47, no. 12, pp. 2123–2129, 2022, doi: **10.1111/ced.15400**.

[8] O. E. Mortensen, S. E. Christensen, and E. Løkkegaard, "The evidence behind the use of LASER for genitourinary syndrome of menopause, vulvovaginal atrophy, urinary incontinence and lichen sclerosus: A state-of-the-art review," *Acta Obstetricia et Gynecologica Scandinavica*, vol. 101, no. 6, pp. 657–692, 2022, doi: **10.1111/aogs.14353**.
[9] N. Mili, S. A. Paschou, A. Armeni, N. Georgopoulos, D. G. Goulis, and I. Lambrinoudaki, "Genitourinary syndrome of menopause: A systematic review on prevalence and treatment," *Menopause*, vol. 28, no. 6, pp. 706–716, 2021, doi: **10.1097/GME.0000000000001752**.
[10] H. S. Raef and S. B. Elmariah, "Vulvar pruritus: A review of clinical associations, pathophysiology and therapeutic management," *Frontiers in Medicine*, vol. 8, Art. no. 649402, 2021, doi: **10.3389/fmed.2021.649402**.
[11] The NAMS 2020 GSM Position Statement Editorial Panel, "The 2020 genitourinary syndrome of menopause position statement of The North American Menopause Society," *Menopause*, vol. 27, no. 9, pp. 976–992, 2020, doi: **10.1097/GME.0000000000001609**.
[12] American College of Obstetricians and Gynecologists' Committee on Practice Bulletins—Gynecology, "Diagnosis and management of vulvar skin disorders: ACOG Practice Bulletin, Number 224," *Obstetrics & Gynecology*, vol. 136, no. 1, pp. e1–e14, 2020, doi: **10.1097/AOG.0000000000003944**.
[13] J. M. Krapf, L. Mitchell, M. A. Holton, and A. T. Goldstein, "Vulvar lichen sclerosus: Current perspectives," *International Journal of Women's Health*, vol. 12, pp. 11–20, 2020, doi: **10.2147/IJWH.S191200**.
[14] S. Dunaway, K. Tyler, and J. Kaffenberger, "Update on treatments for erosive vulvovaginal lichen planus," *International Journal of Dermatology*, vol. 59, no. 3, pp. 297–302, 2020, doi: **10.1111/ijd.14692**.
[15] F. R. Pérez-López and P. Vieira-Baptista, "Lichen sclerosus in women: A review," *Climacteric*, vol. 20, no. 4, pp. 339–347, 2017, doi: **10.1080/13697137.2017.1343295**.
[16] M. L. Marnach and R. R. Torgerson, "Vulvovaginal issues in mature women," *Mayo Clinic Proceedings*, vol. 92, no. 3, pp. 449–454, 2017, doi: **10.1016/j.mayocp.2016.10.031**.
[17] M. Hum and M. Dytoc, "A dermatologist's approach to genitourinary syndrome of menopause," *Journal of Cutaneous Medicine and Surgery*, vol. 21, no. 5, pp. 418–424, 2017, doi: **10.1177/1203475417708165**.
[18] F. M. Lewis, "Vulval symptoms after the menopause—Not all atrophy!," *Post Reproductive Health*, vol. 21, no. 4, pp. 146–150, 2015, doi: **10.1177/2053369115608019**.
[19] A. Guerrero and A. Venkatesan, "Inflammatory vulvar dermatoses," *Clinical Obstetrics and Gynecology*, vol. 58, no. 3, pp. 464–475, 2015, doi: **10.1097/GRF.0000000000000125**.
[20] R. M. Brotman, M. D. Shardell, P. Gajer, *et al*., "Association between the vaginal microbiota, menopause status, and signs of vulvovaginal atrophy," *Menopause*, vol. 21, no. 5, pp. 450–458, 2014, doi: **10.1097/GME.0b013e3182a4690b**.

Issue 4, Year 2, Volume 1, No. 02, July-December 2026
E-ISSN: 3122-3591, P-ISSN: 3122-3753
Review International Science Journal

Issue 4, Year 2, Volume 1, No. 02, July-December 2026
E-ISSN: 3122-3591, P-ISSN: 3122-3753
Review International Science Journal